

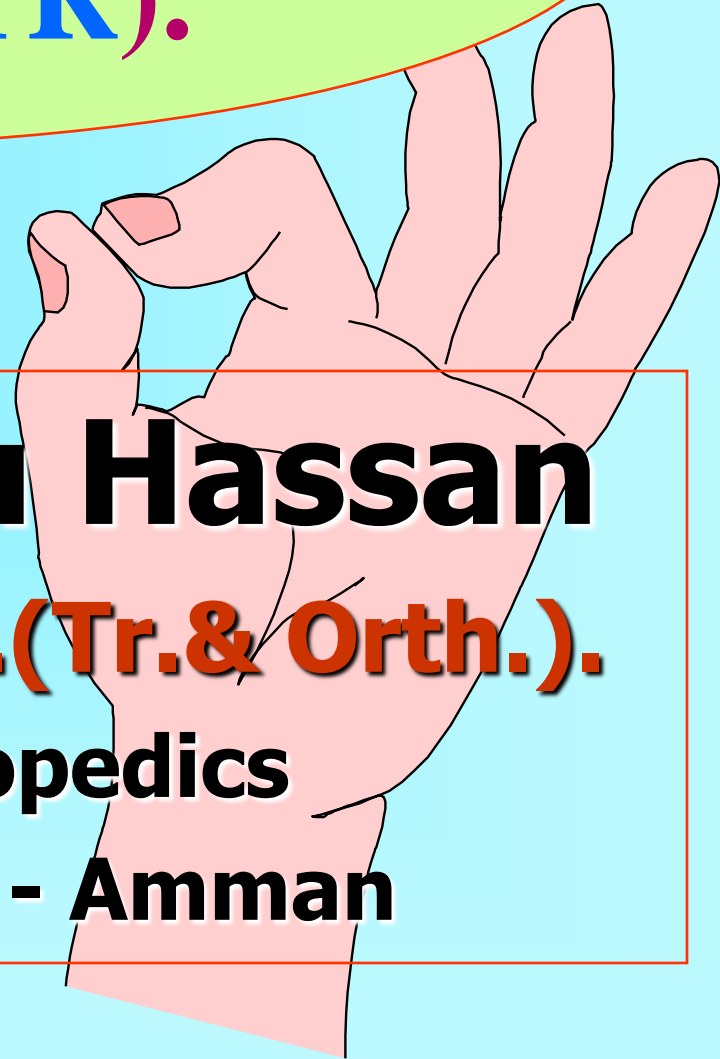
**Endoscopically Assisted  
CTR (EACTR).**

**Freih Odeh Abu Hassan**

**F.R.C.S.(Eng.), F.R.C.S.(Tr.& Orth.).**

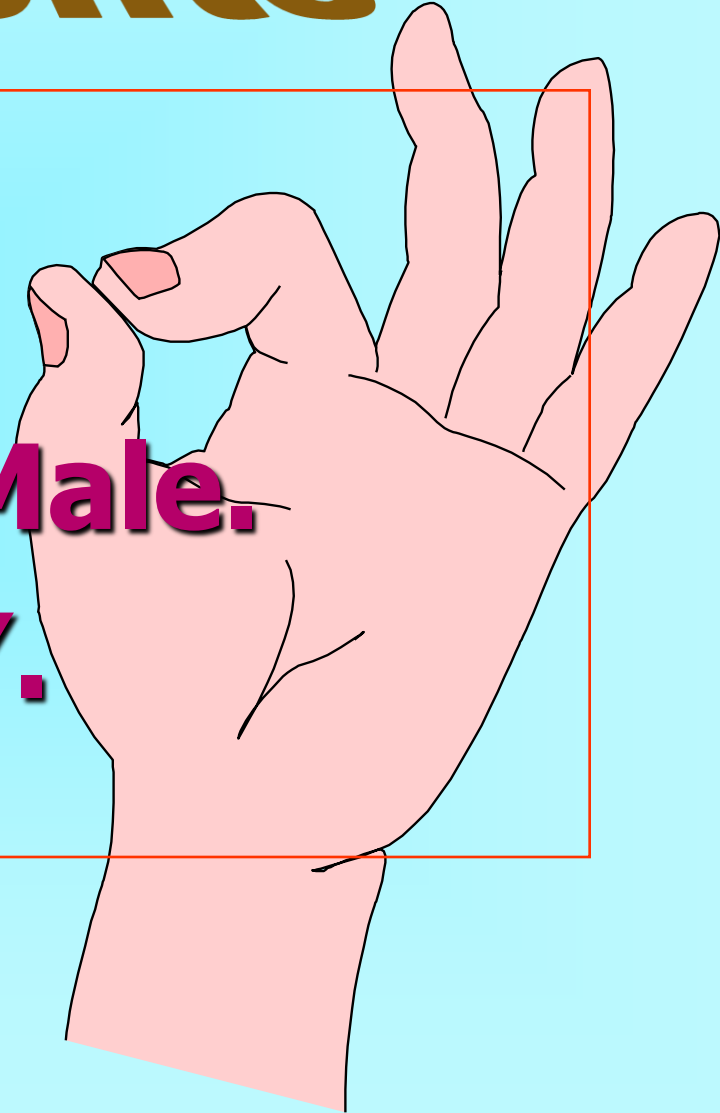
**Professor of Orthopedics**

**University of Jordan - Amman**



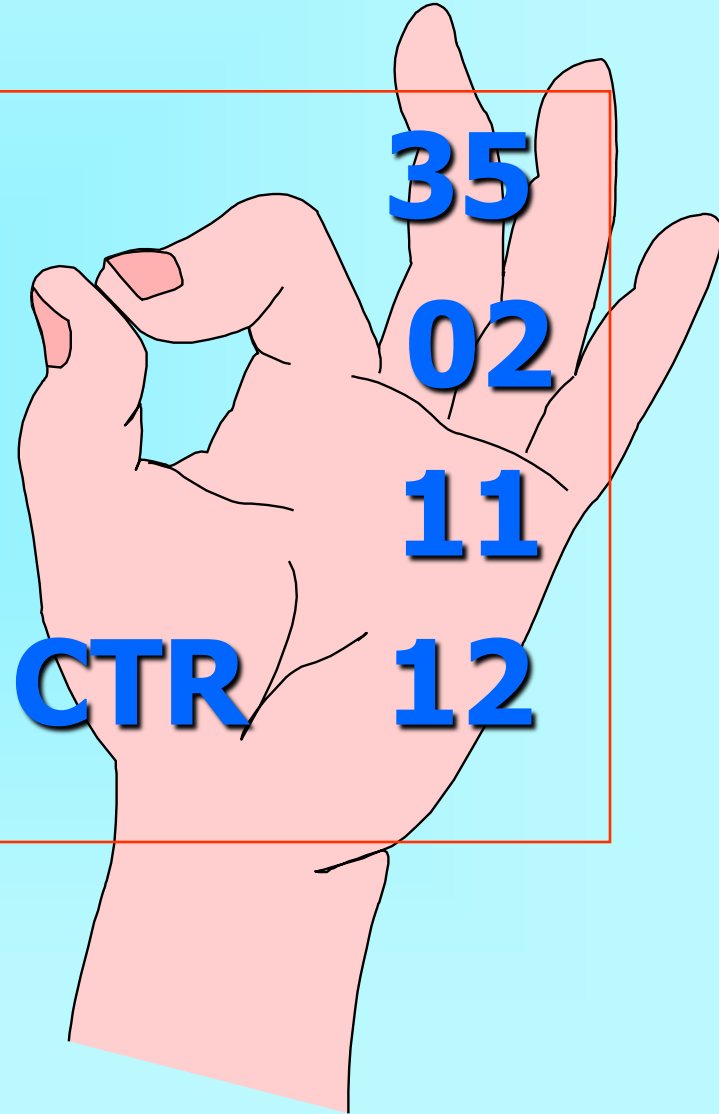
# ~~72~~ 72 patients

- \* 89 Hand.
- \* 68 Female/ 4 Male.
- \* Age : 26 – 67 Y.



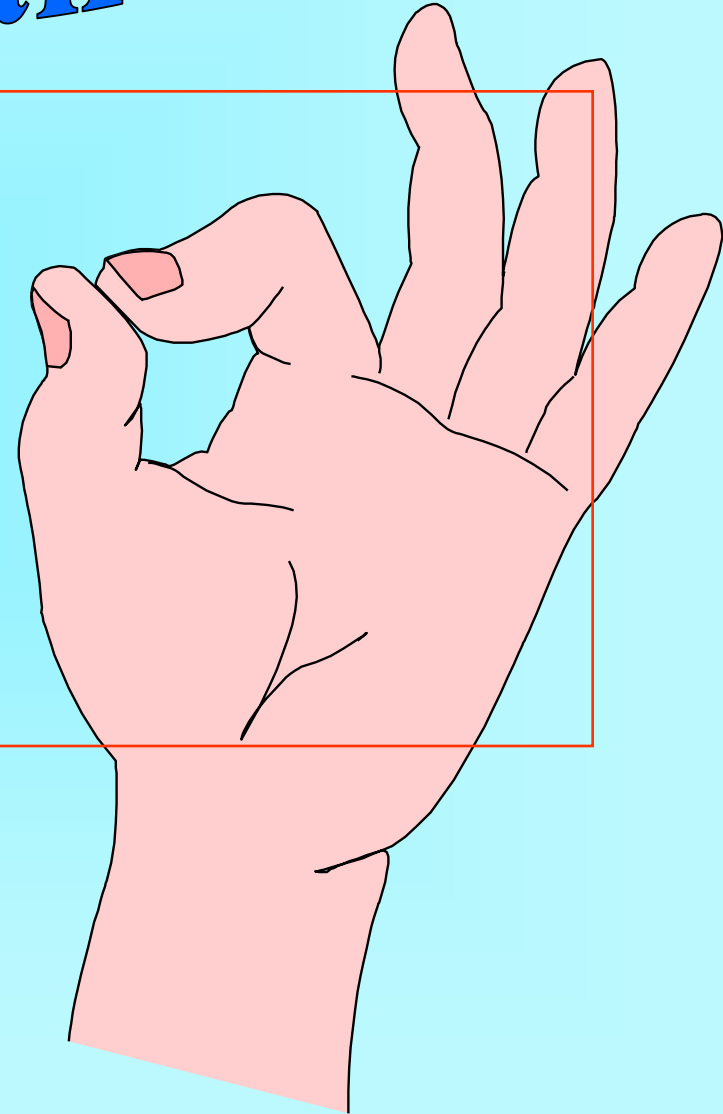
# Associated problems

* DM	35
* Gout	02
* Hypertension	11
* Previous Open CTR	12



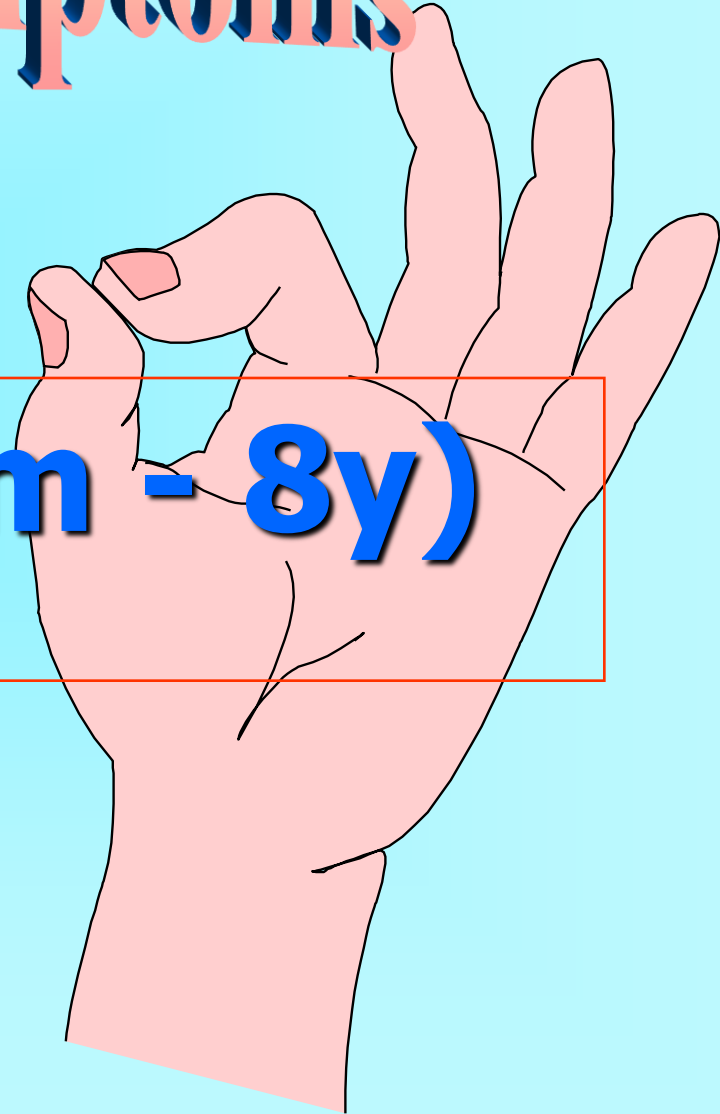
# Affected Hand

<b>*</b>	<b>Bilat.</b>	<b>14</b>
<b>*</b>	<b>Right</b>	<b>47</b>
<b>*</b>	<b>Lt.</b>	<b>14</b>




# Duration of symptoms

\* 1.2 year (6m - 8y)



# Diagnosis

**\* 71 hand**

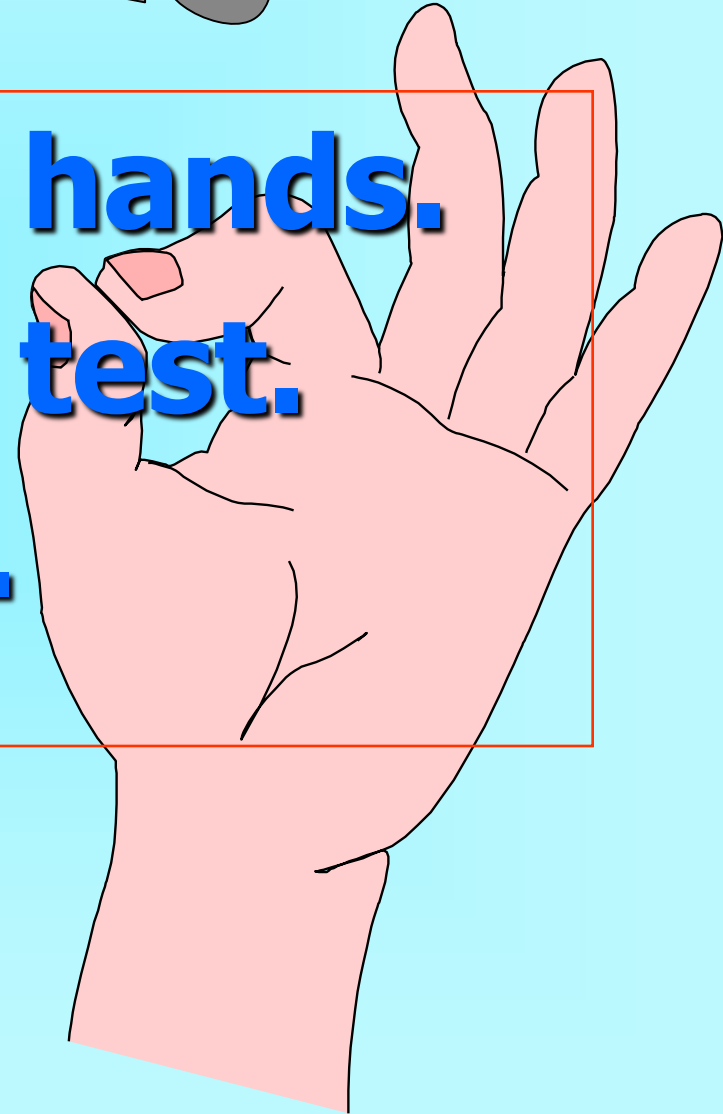



# Diagnosis

**Clinical Dx : 18 hands.**

**- Compression test.**

**- Phalen's test.**



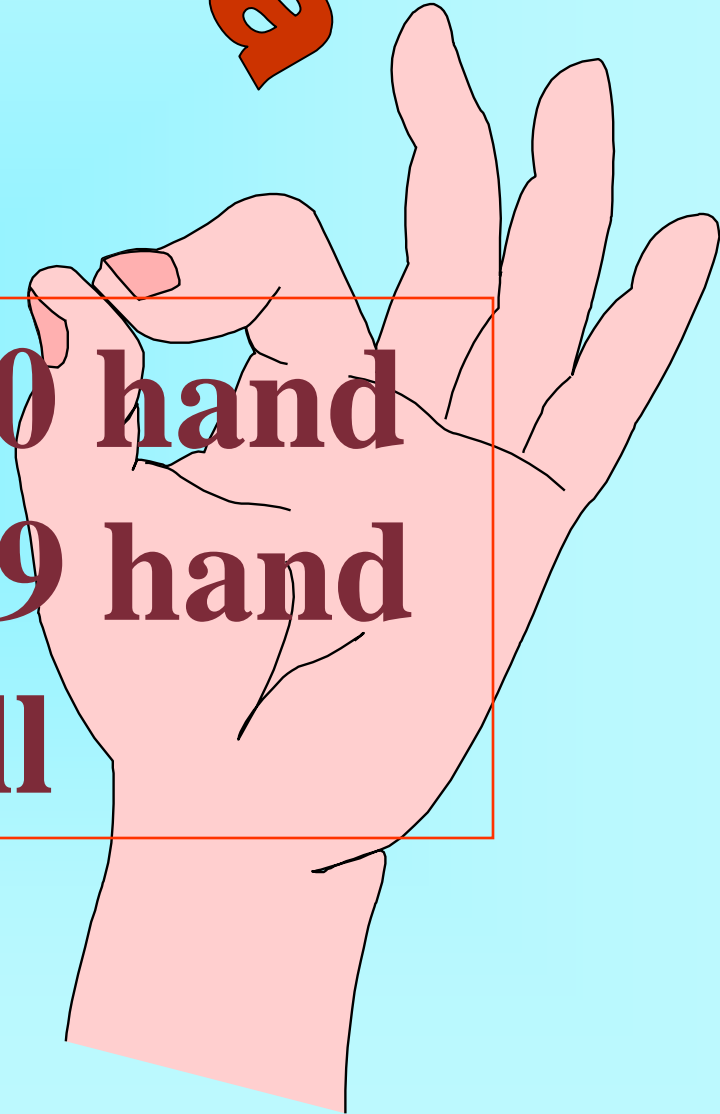

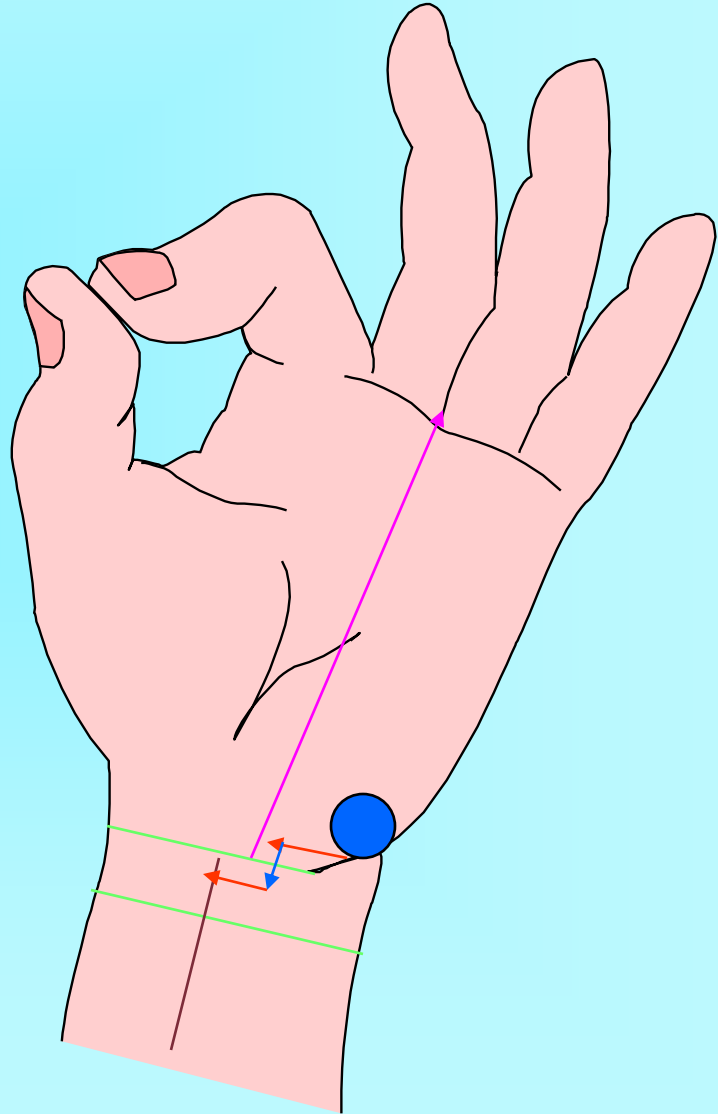
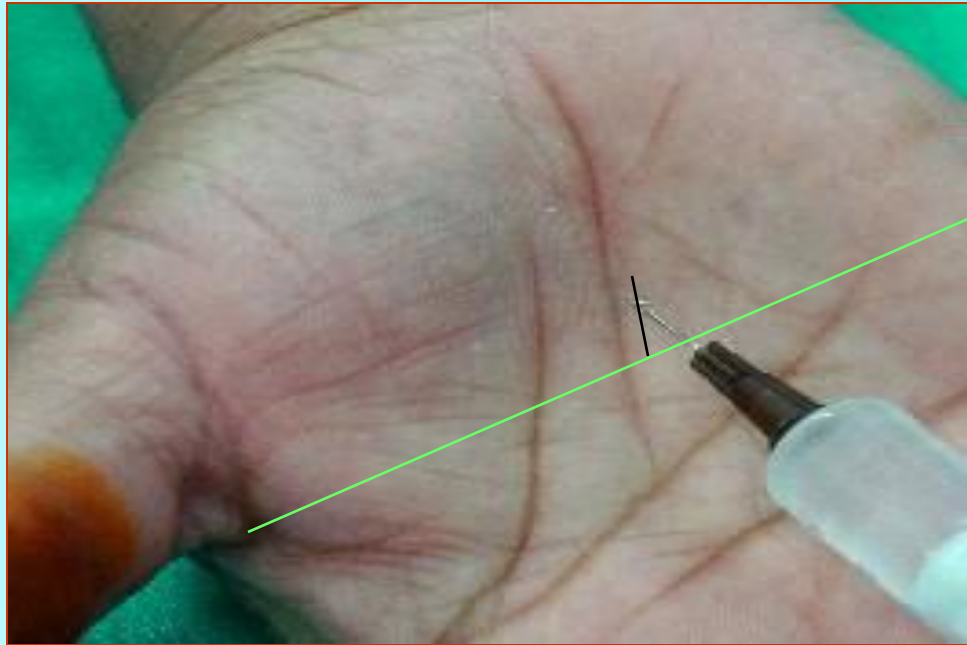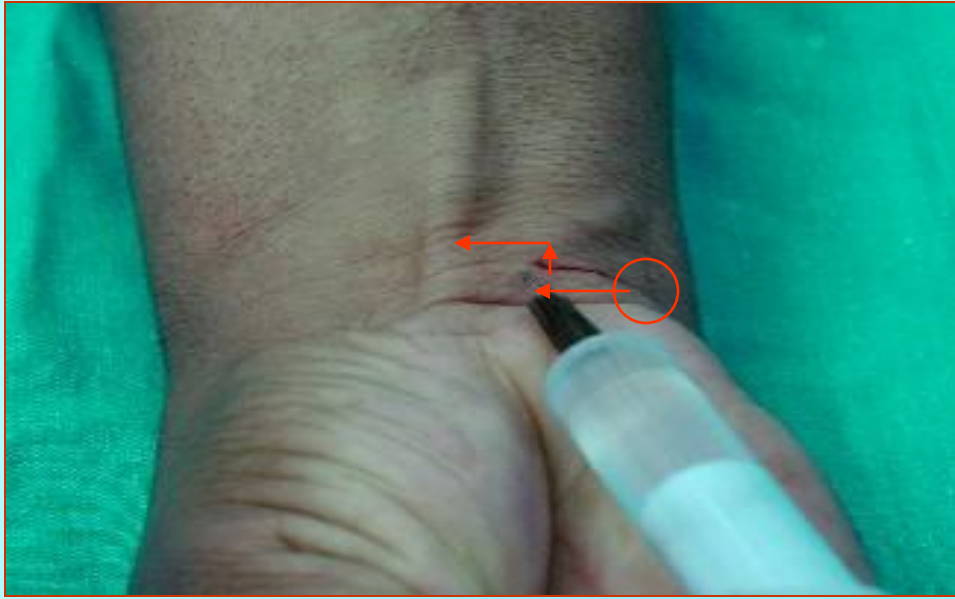
# Surgical Technique

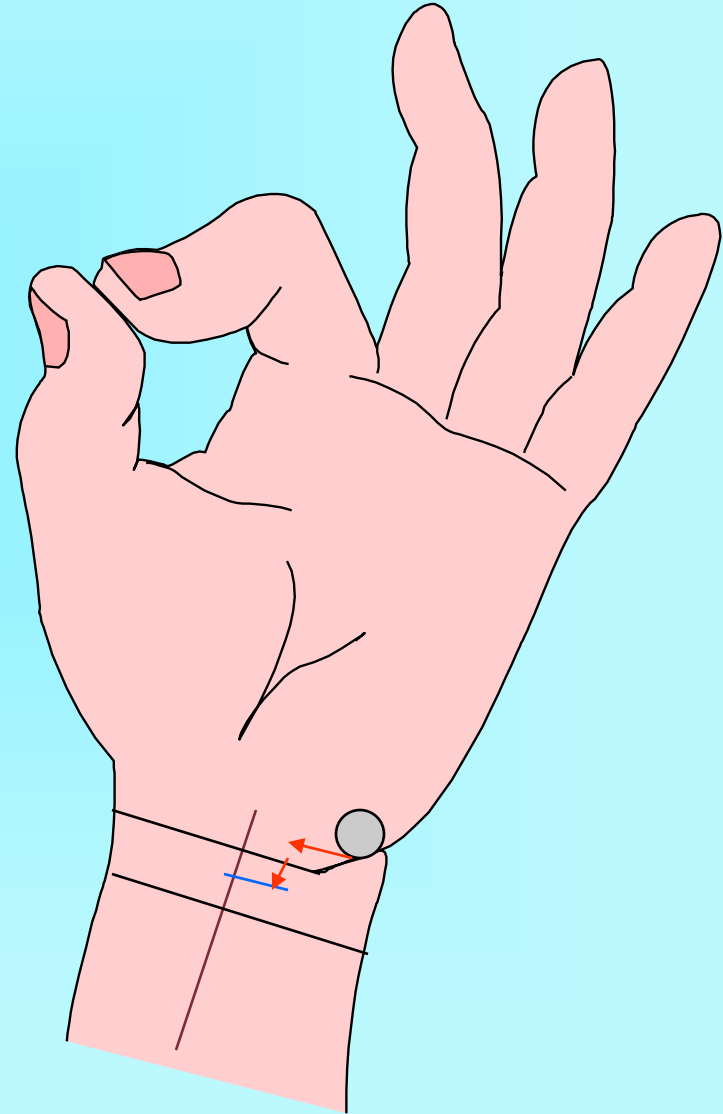
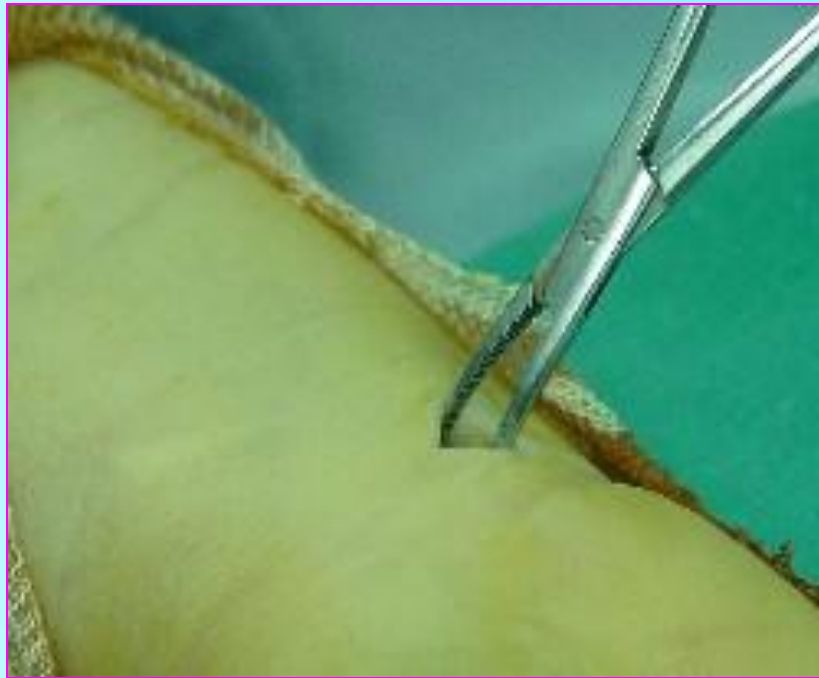
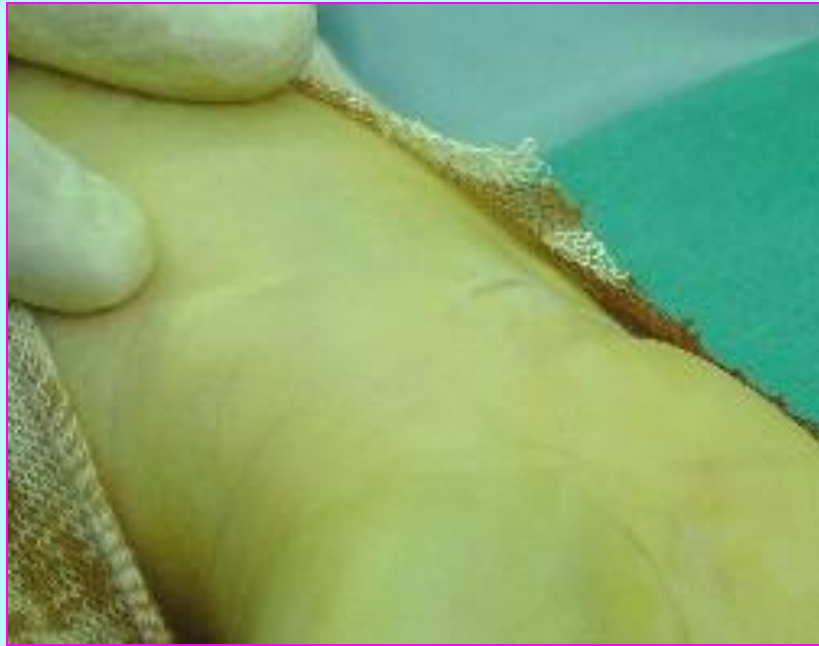
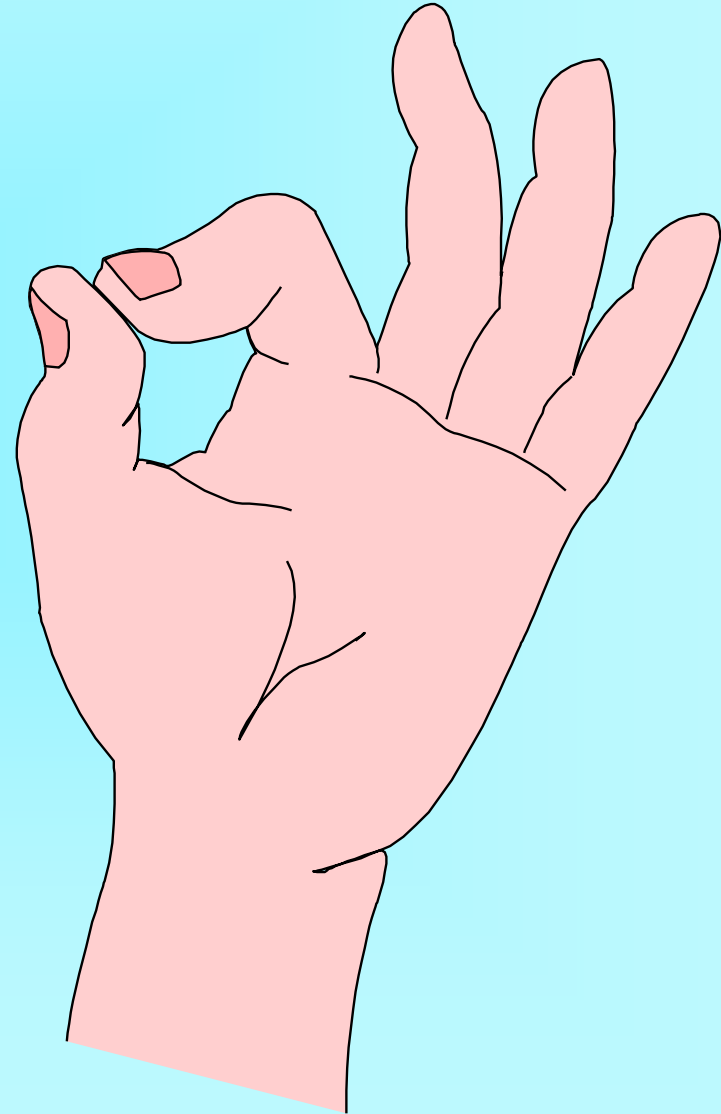
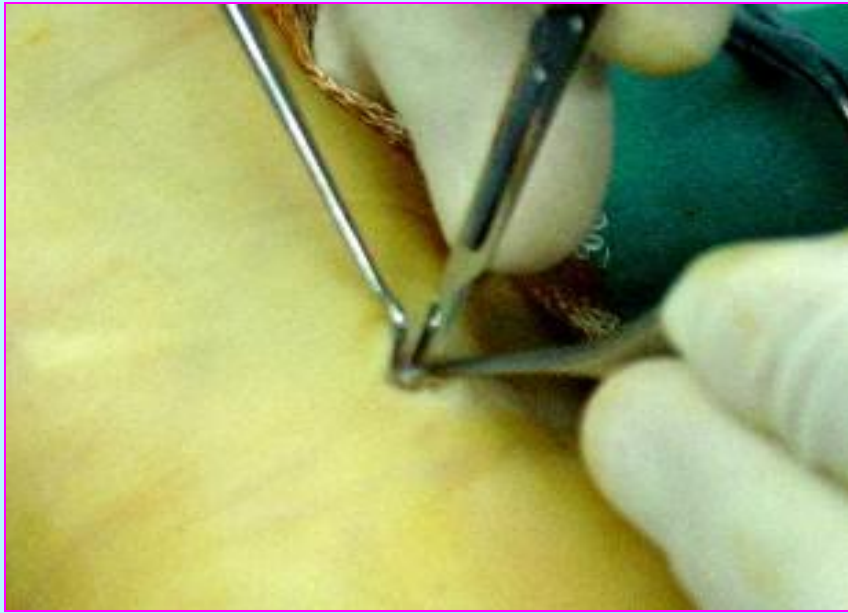
# Anaesthesia

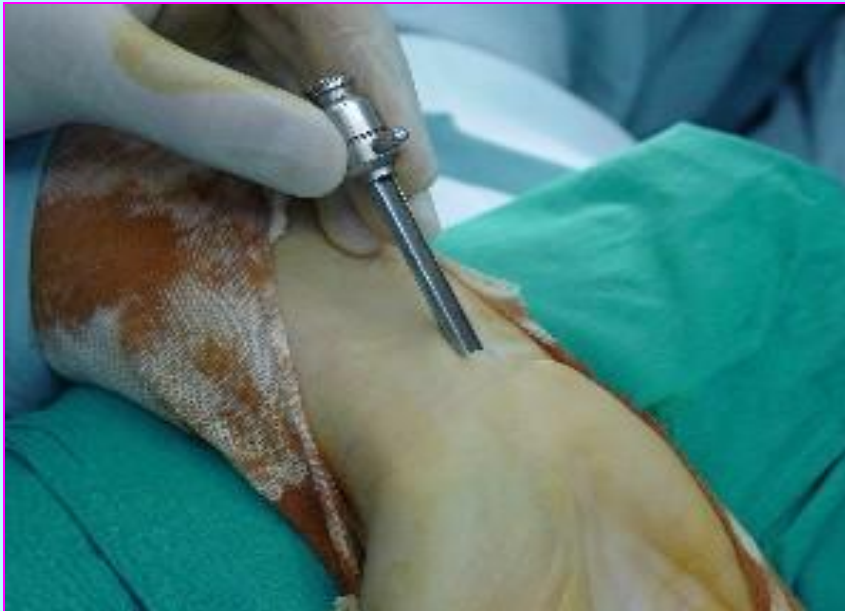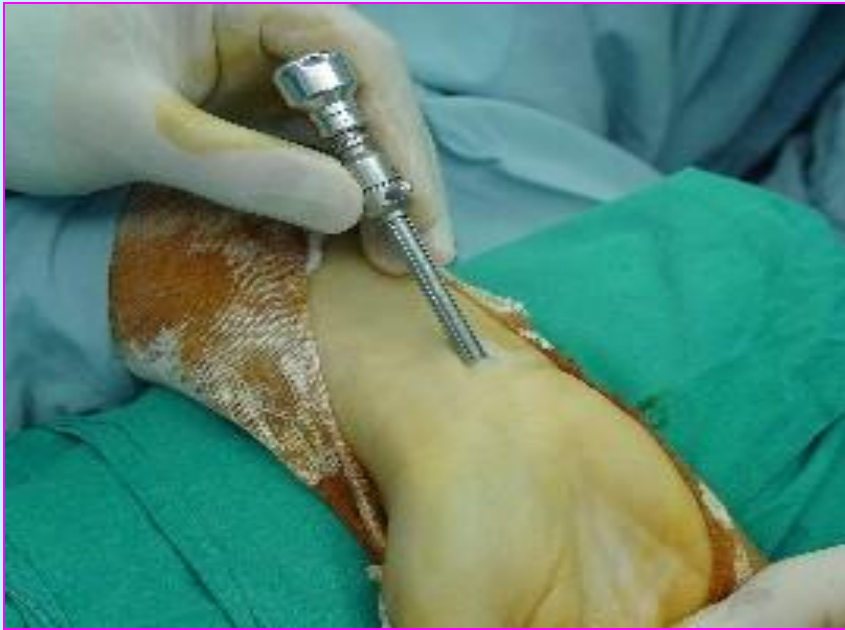- \* **Local An.** 30 hand
- \* **General An.** 59 hand
- \* **Tourniquet** all



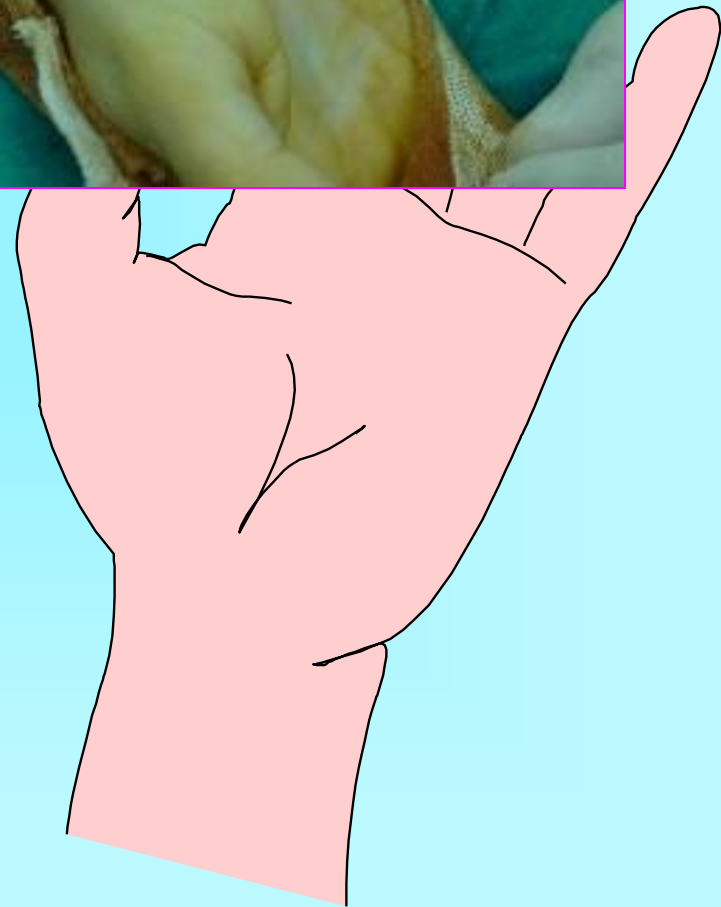
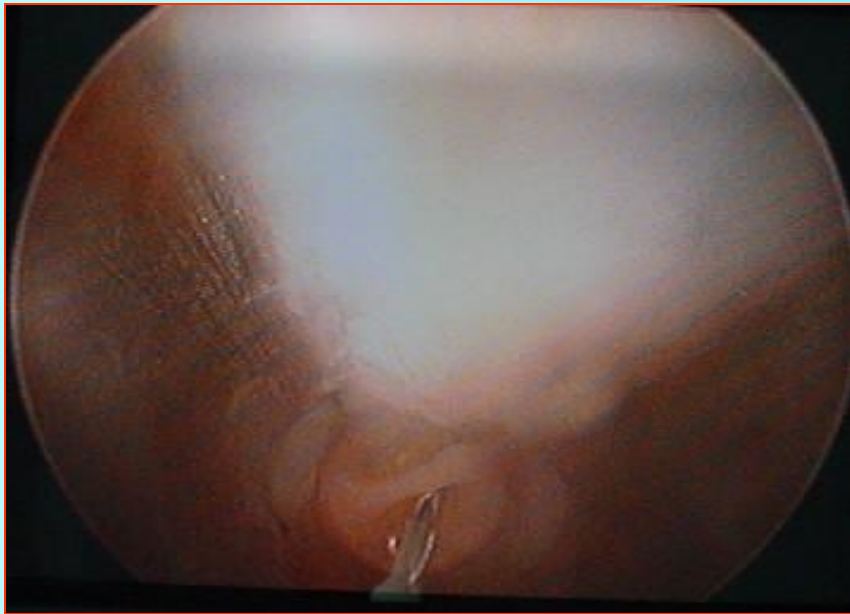
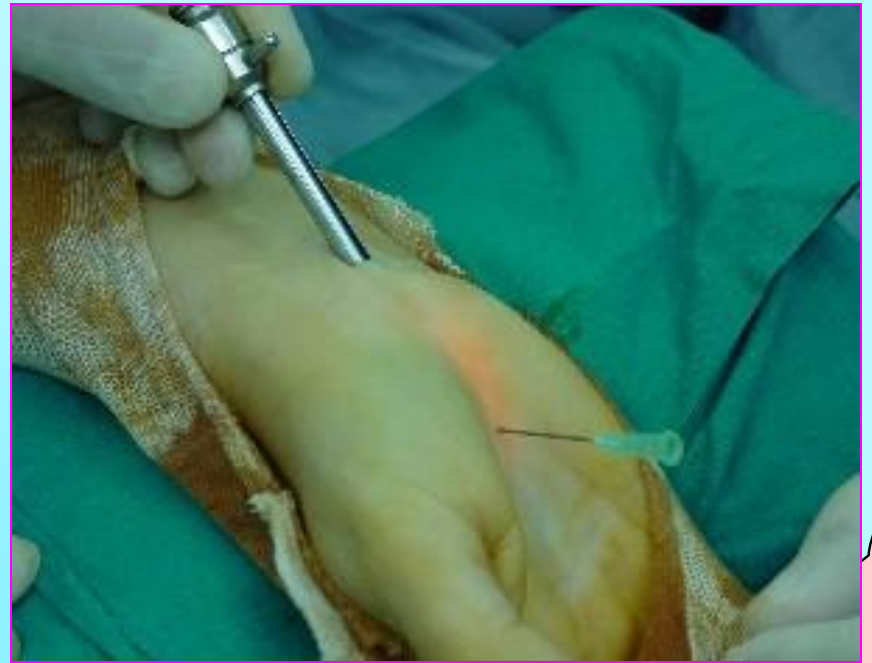
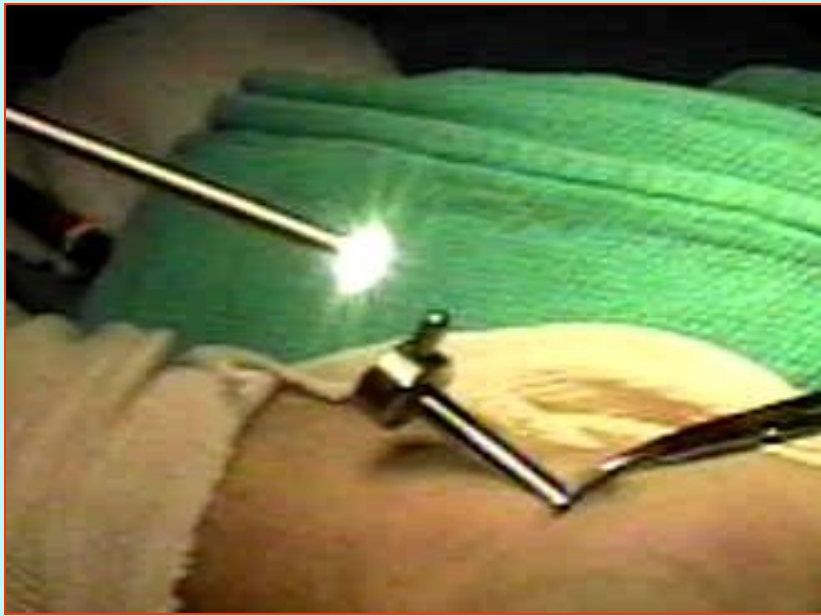
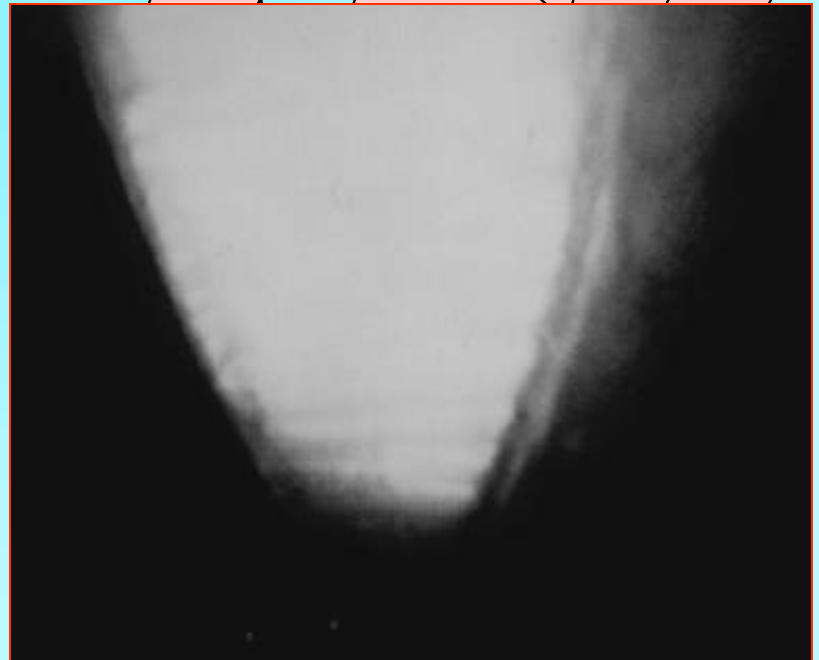
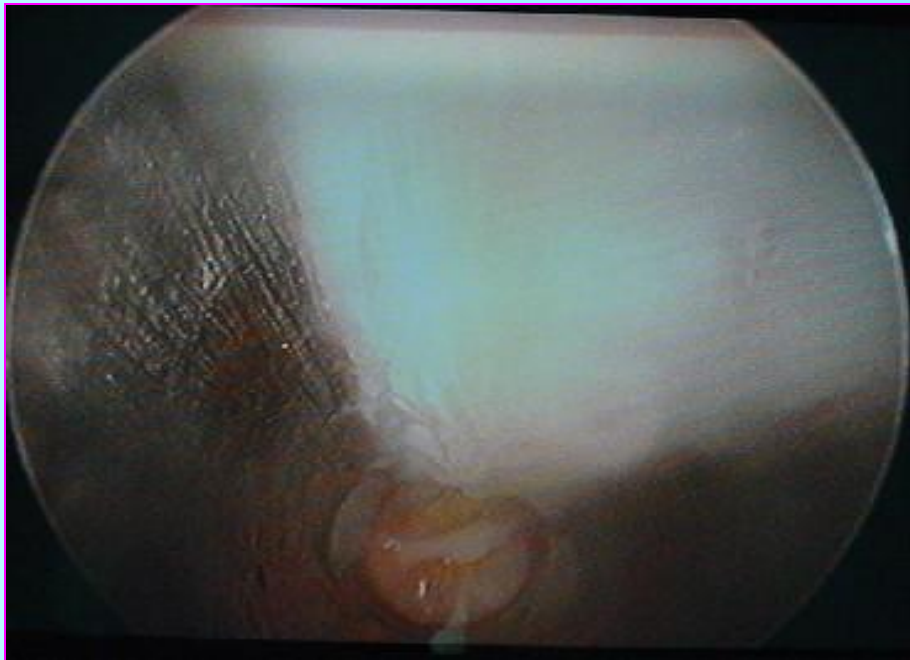
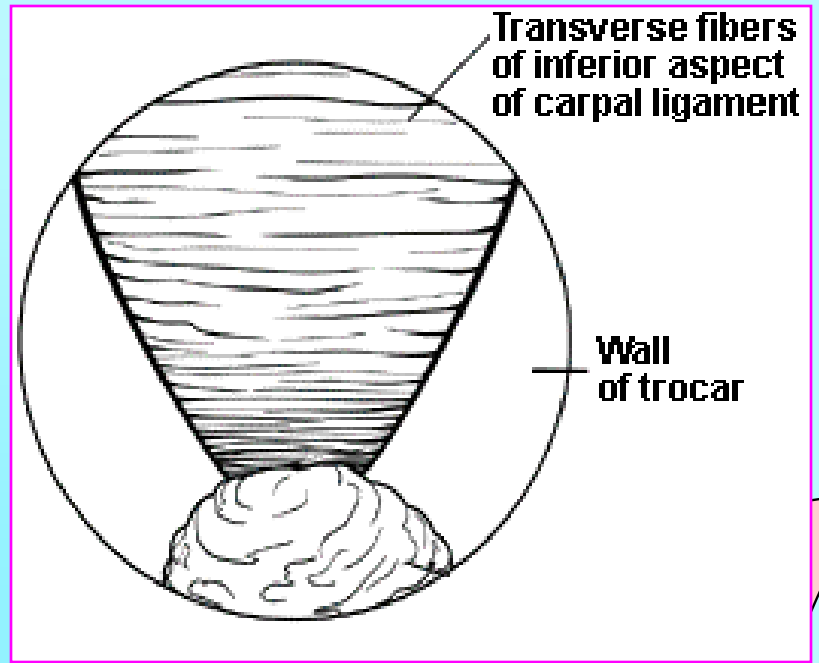


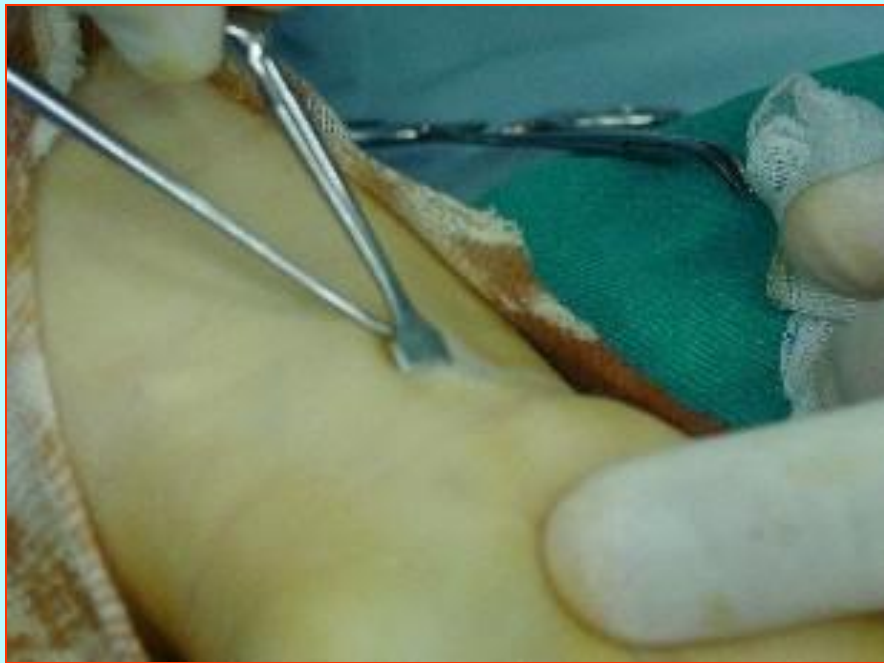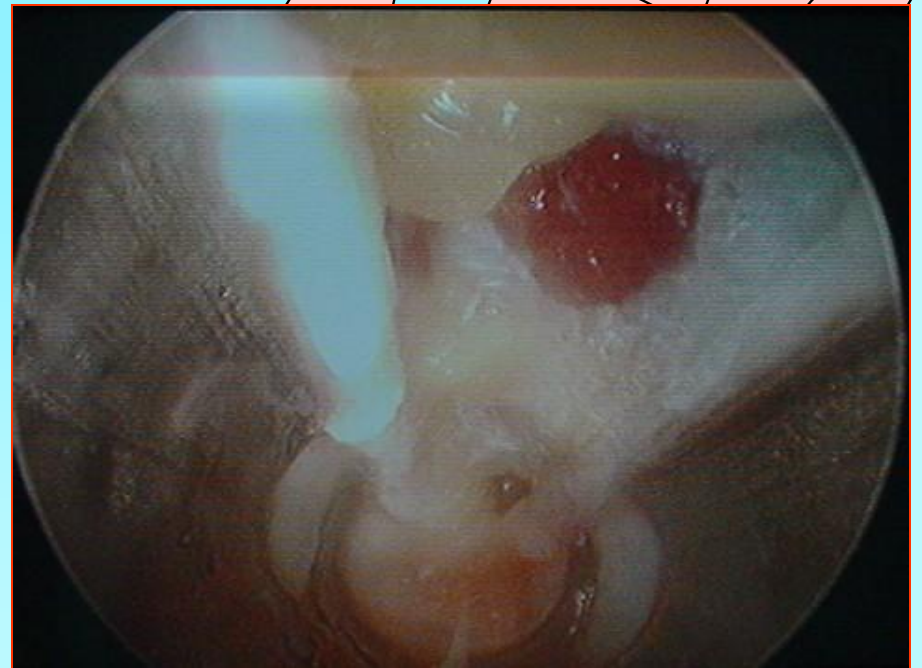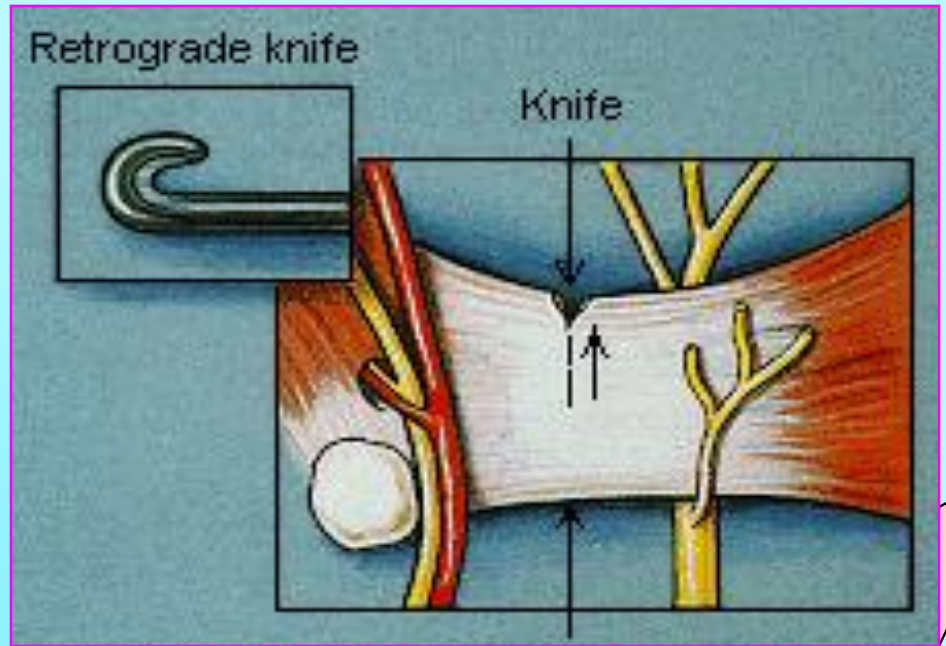




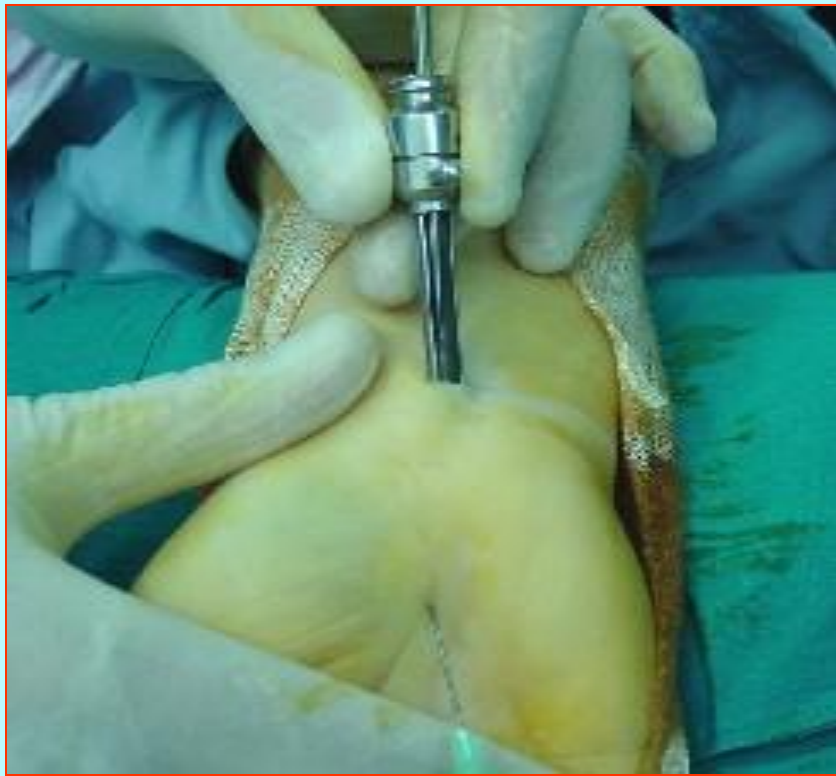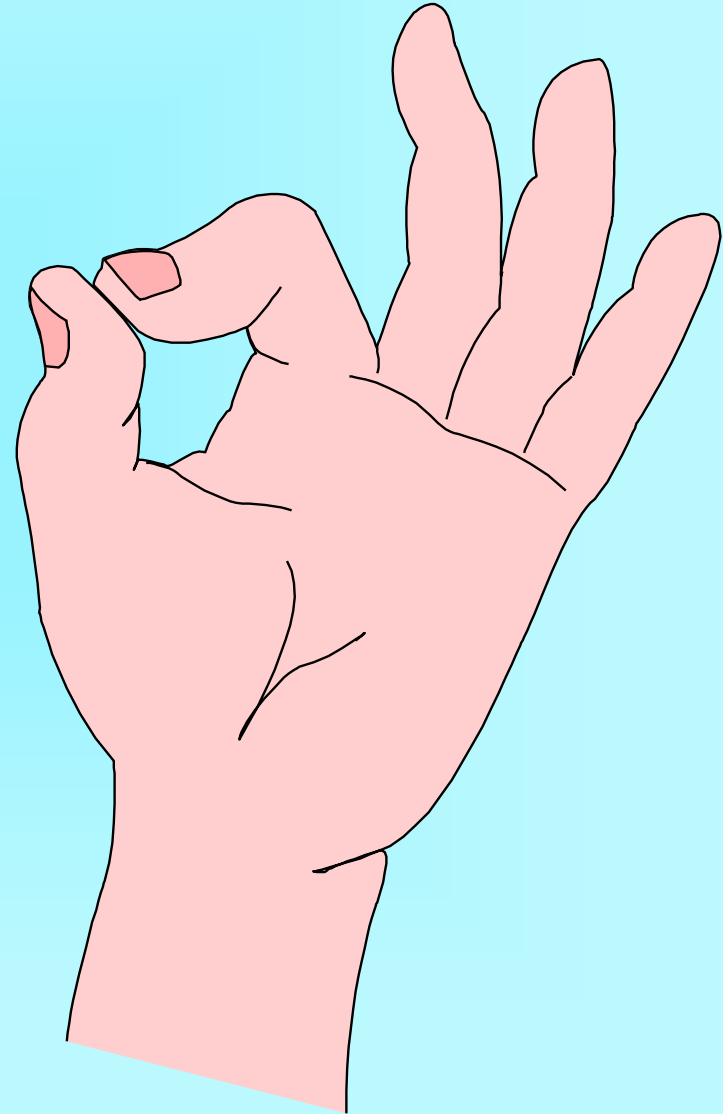
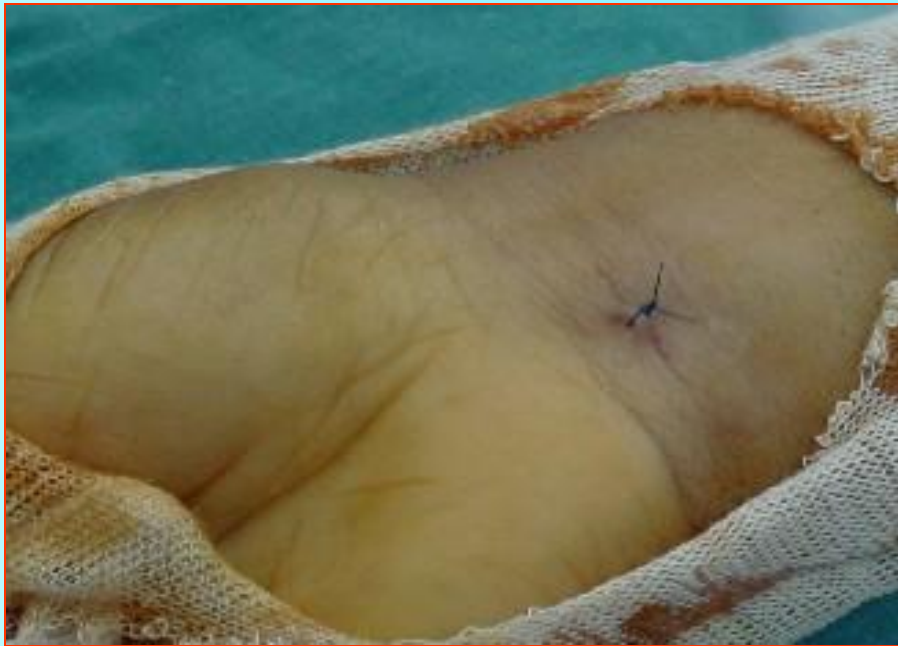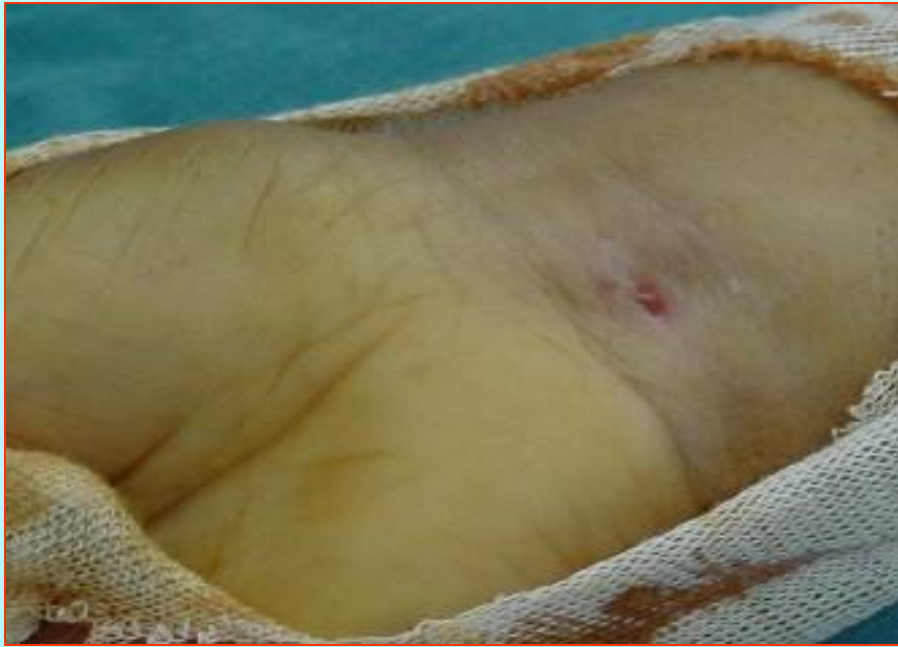












# Problems



**\* Ulnar N. neuropraxia 01**

**\* RSD 01**

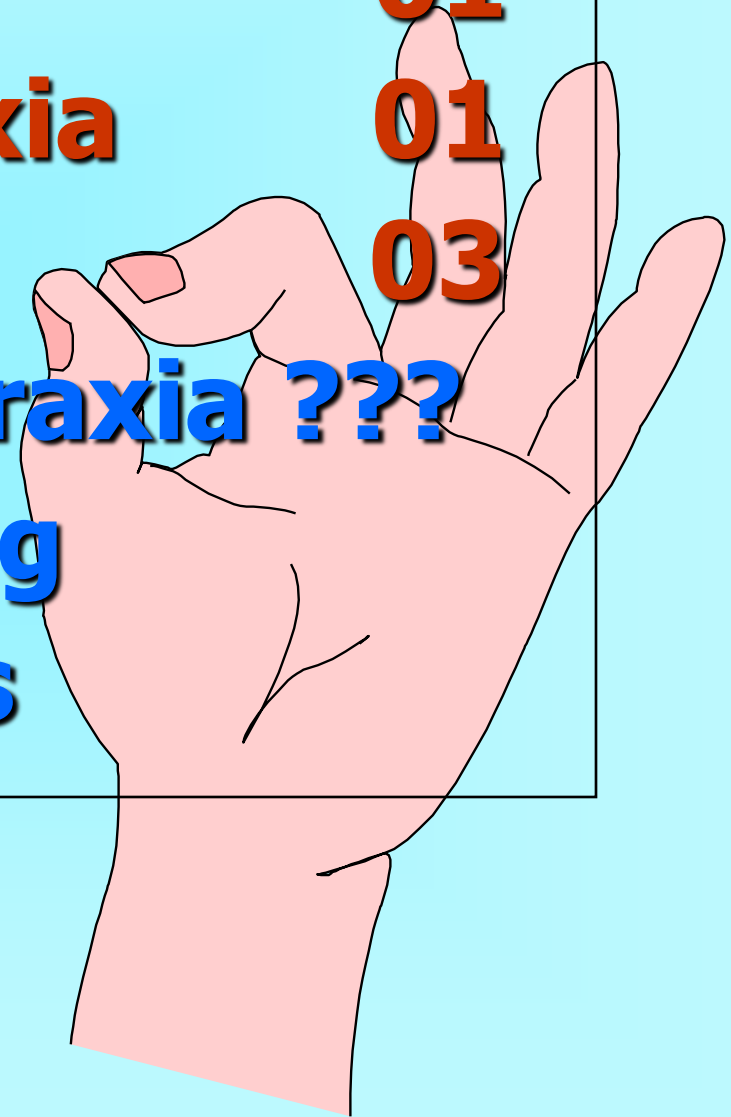
**\* Digital N neuropaxia 01**

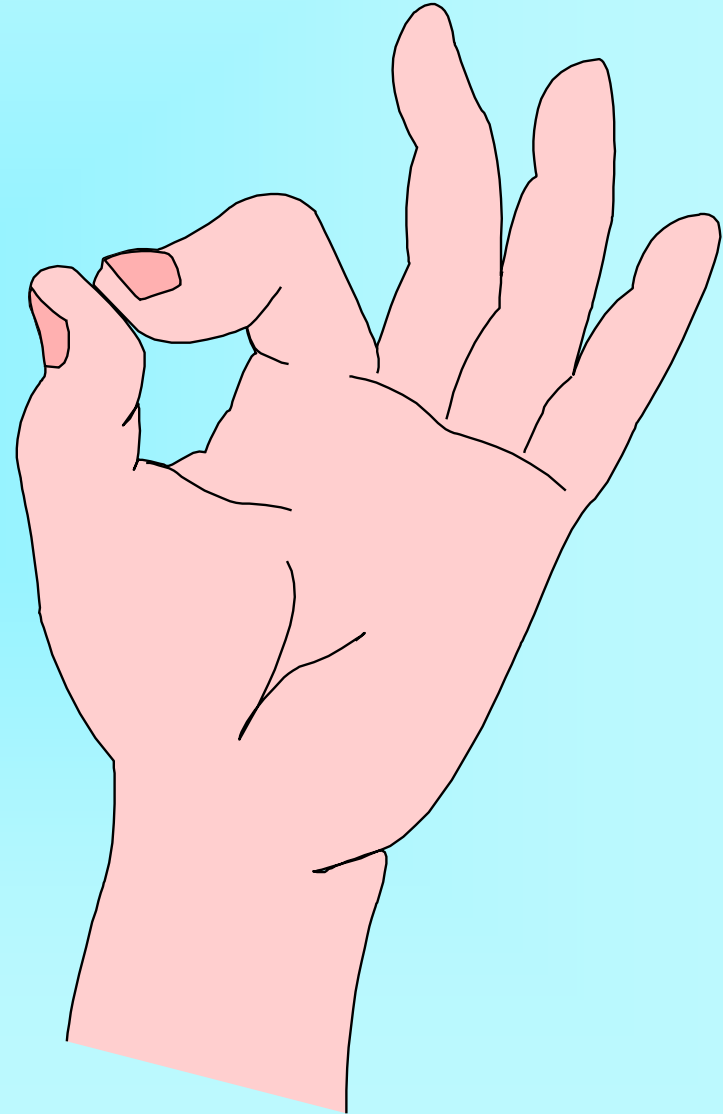
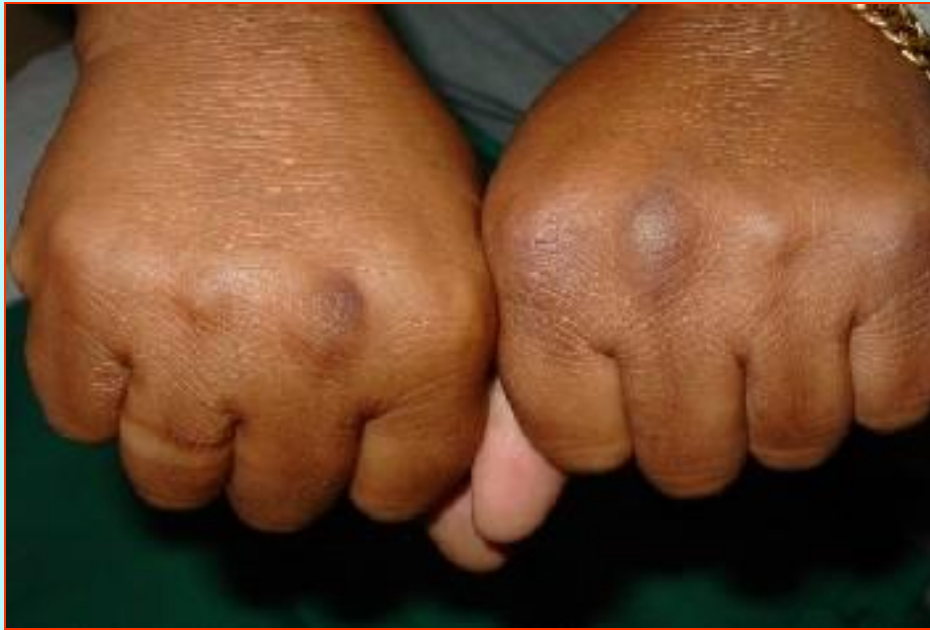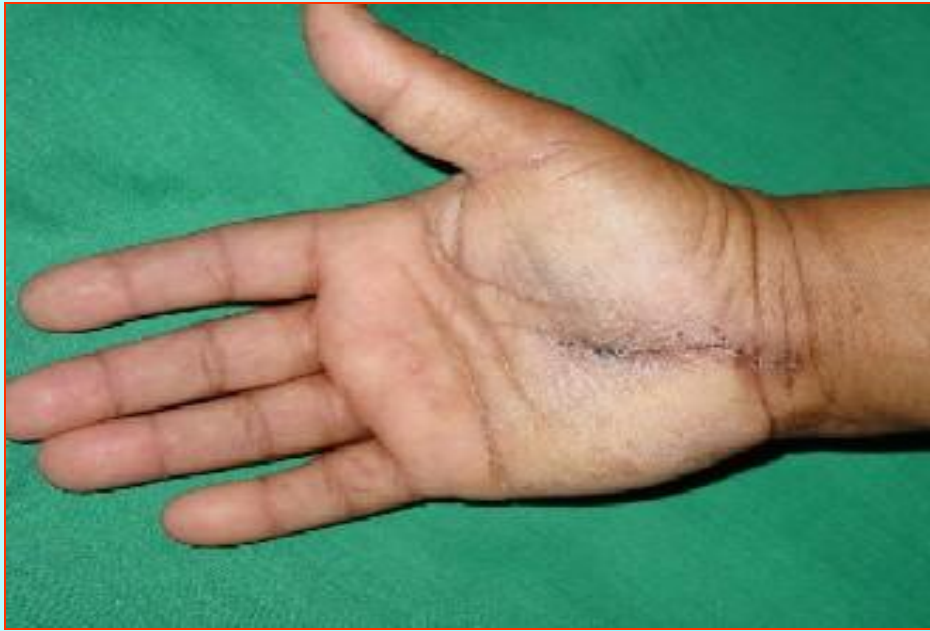**\* Re exploration 03**

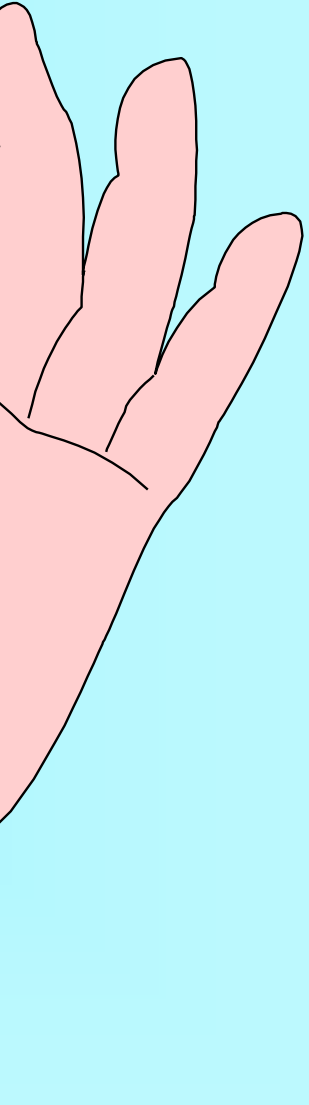
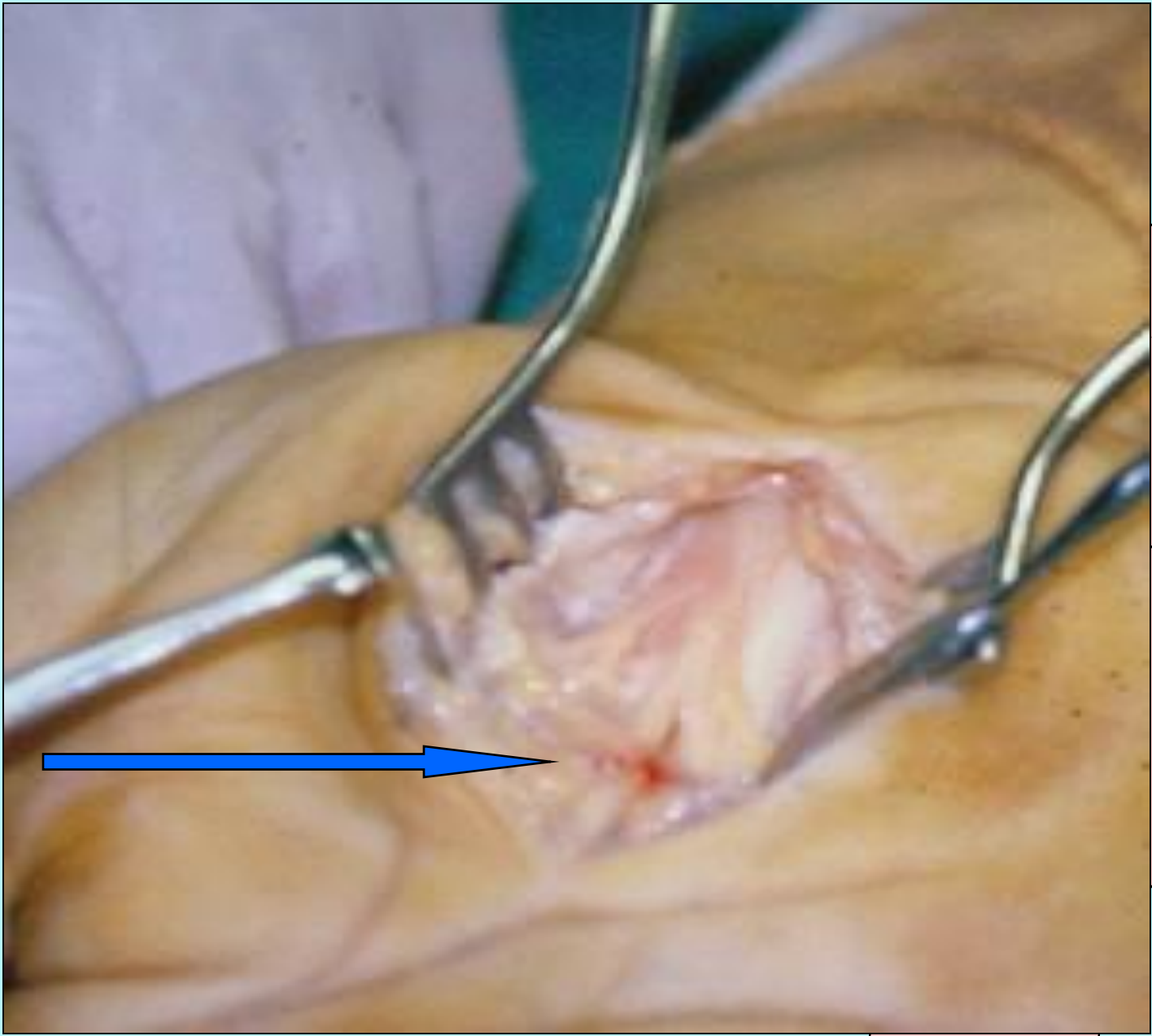
**+ Digital N. neuropraxia ???**

**+ interpillar scarring**

**+ Digital N. Fibrosis**









# Tenderness Post Op

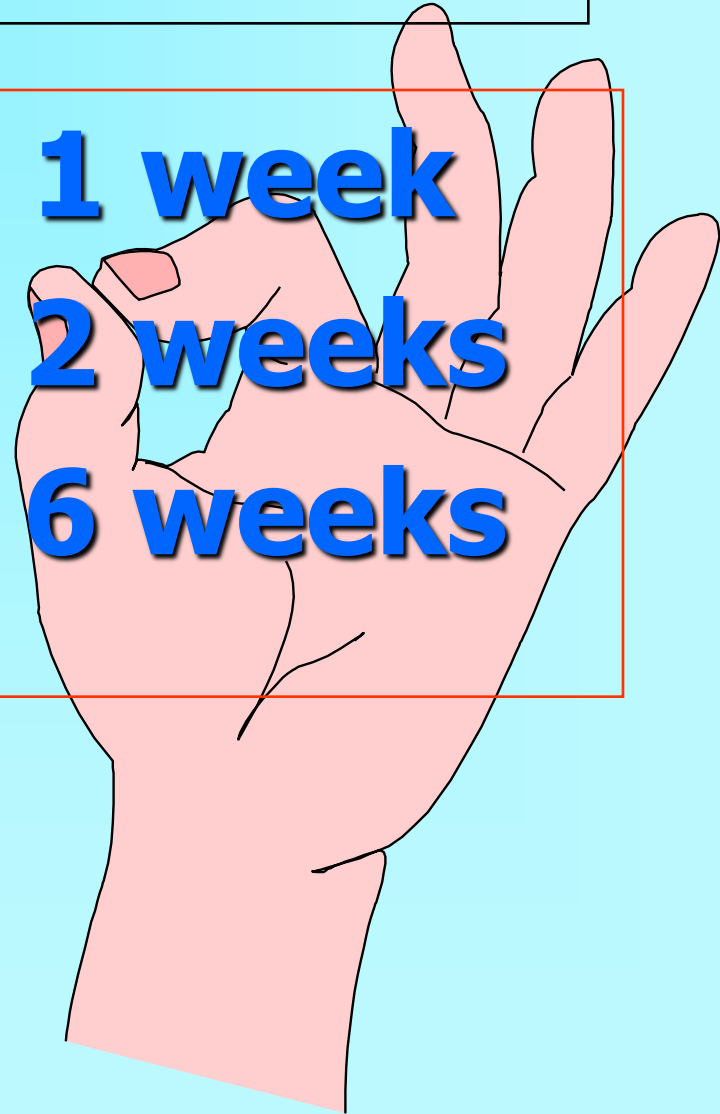Site	Intensity	2W	4W	12W
Scar	Mild	06	00	00
	Moderate	01	00	00
	Severe	00	00	00
Pillar	Mild	03	02	00
	Moderate	04	00	00
	Severe	00	00	00

# Return to ADL

\* **61 patient = 1 week**

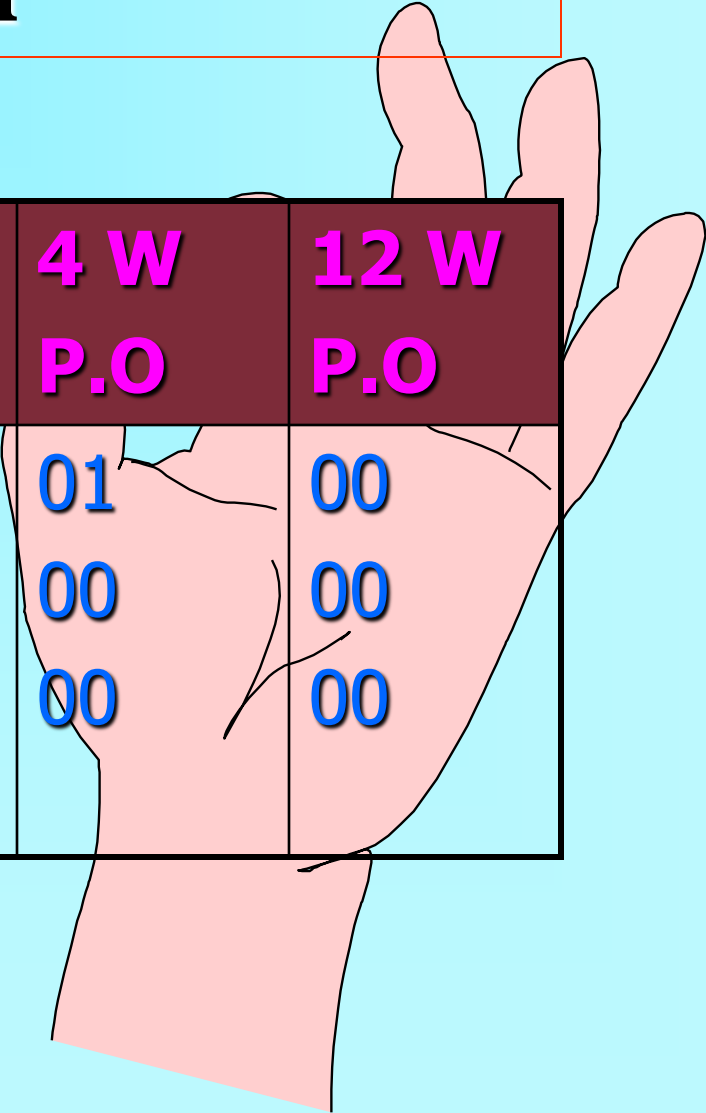
\* **08 patients = 2 weeks**

\* **03 patients = 6 weeks**



# Patient-Reported Symptoms

## Night pain

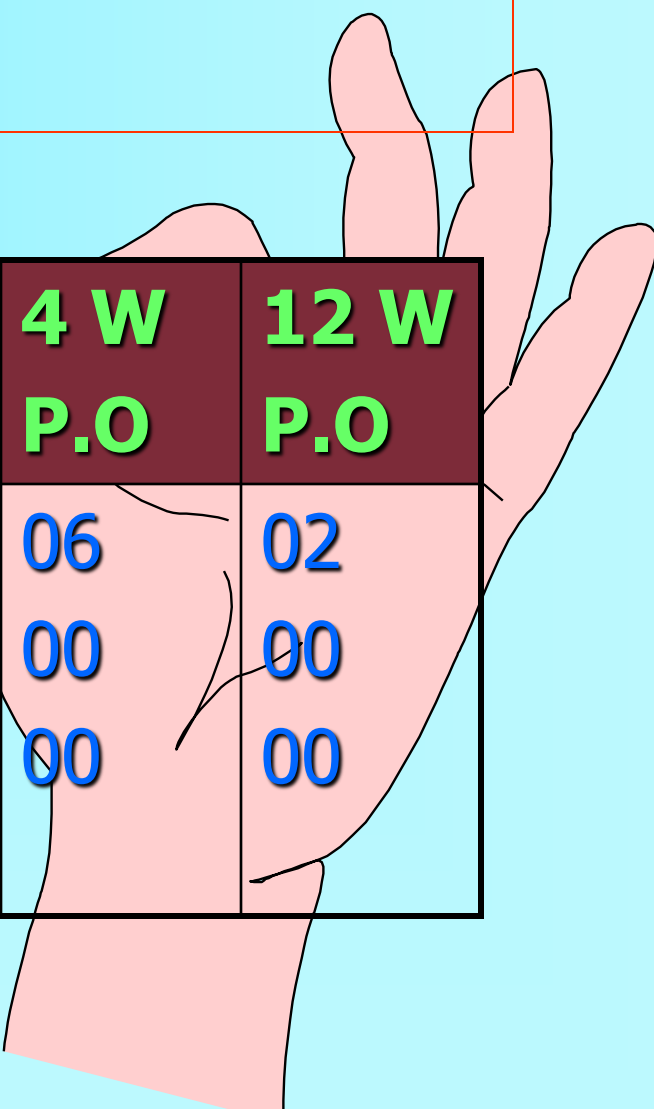


<b>C/O</b>	<b>severity</b>	<b>Pre Op.</b>	<b>2 W P.O</b>	<b>4 W P.O</b>	<b>12 W P.O</b>
<b>Night pain</b>	Mild	04	07	01	00
	Moderate	23	05	00	00
	Severe	63	00	00	00



# Patient-Reported Symptoms

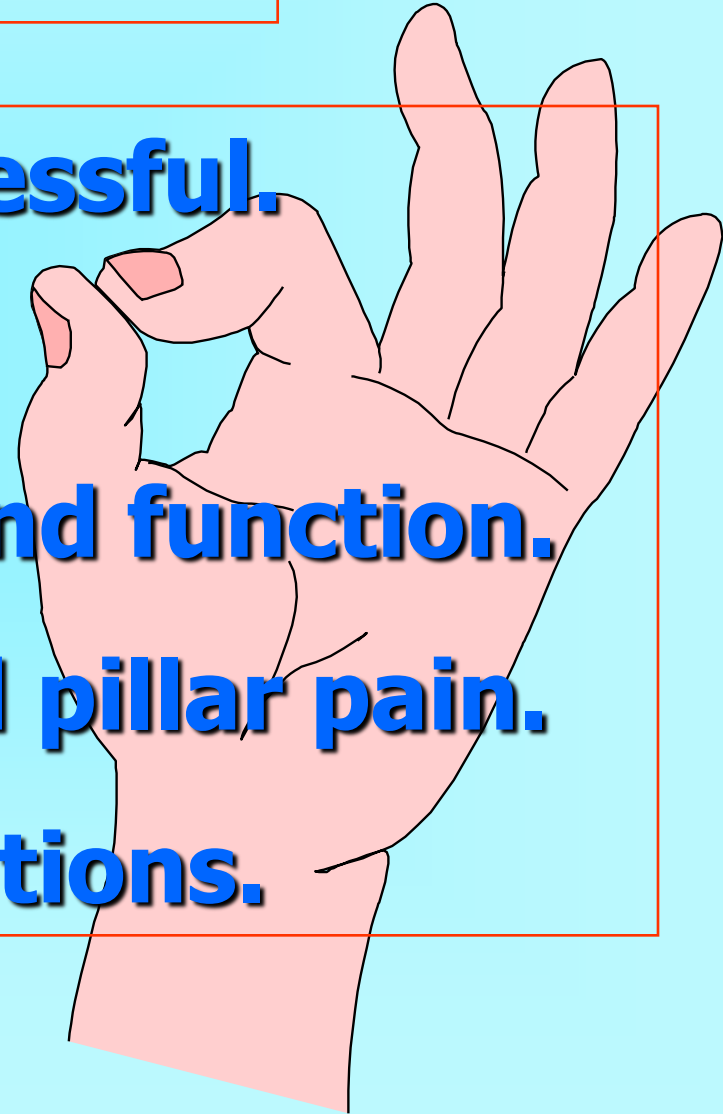
## Numbness

An illustration of a right hand with a pinkish-red tint, showing signs of numbness or swelling. The hand is positioned behind the table, with fingers slightly spread and the palm facing forward.

<b>C/O</b>	<b>Severity</b>	<b>Pre Op.</b>	<b>2 W P.O</b>	<b>4 W P.O</b>	<b>12 W P.O</b>
<b>Numbness</b>	Mild	04	11	06	02
	Moderate	23	00	00	00
	Severe	63	00	00	00

# Conclusion

- \* **Simple, Safe & Successful.**
- \* **Needs training.**
- \* **Early recovery of hand function.**
- \* **Less tender scar and pillar pain.**
- \* **Temporary complications.**



Thank

