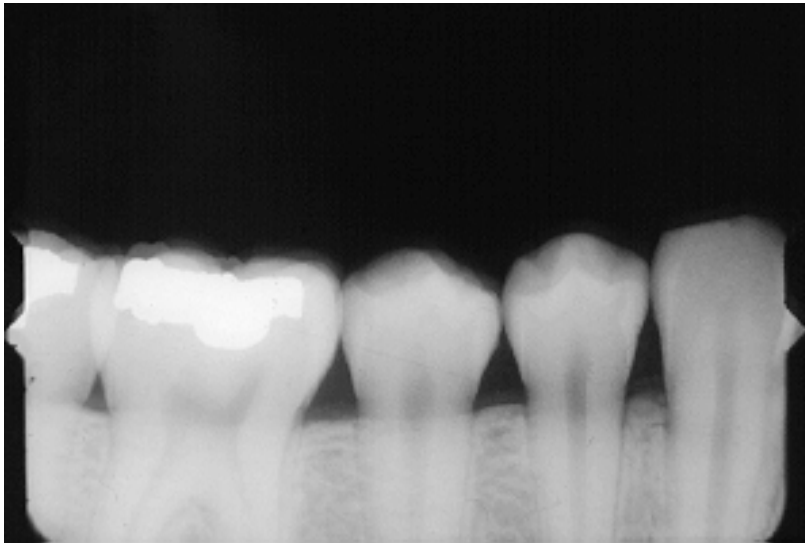


Please critique the following radiographs:

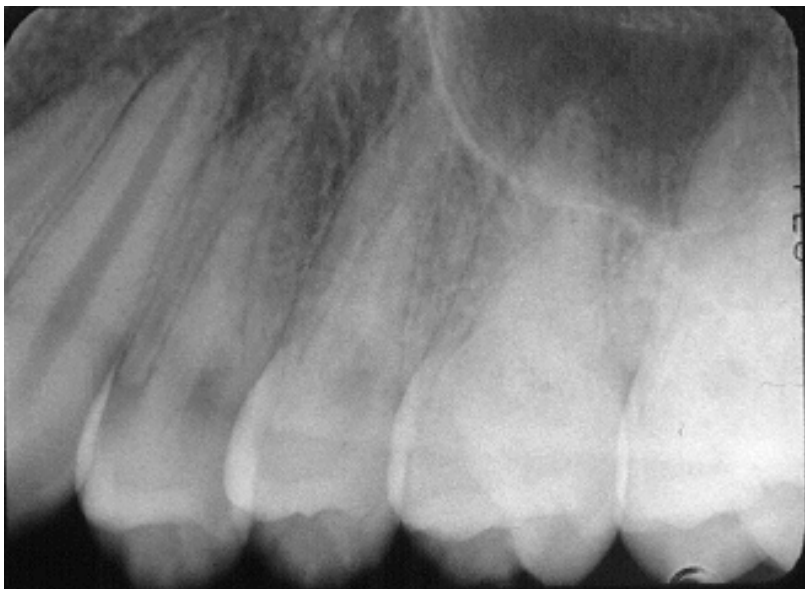Include in your critique the problem (if any), why it happened, and how to fix it. Please respond **individually** by email (a_hadidi@ju.edu.jo or a_7adidi@yahoo.com) no later than Thursday Dec the 10th at 12:00 midnight. No group work is accepted.

a.



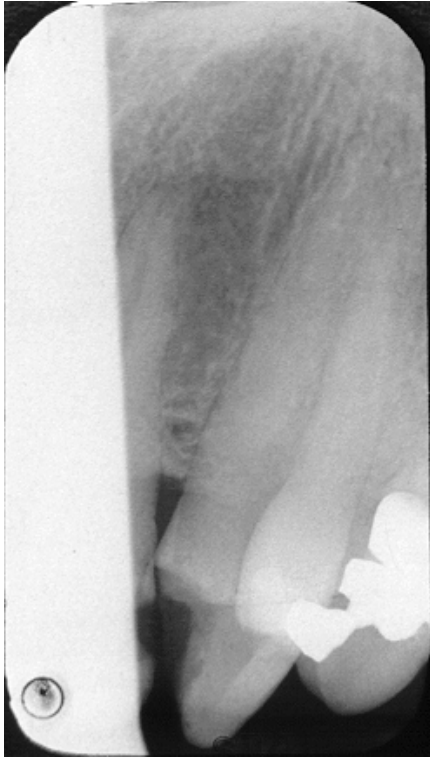Apices missing; Film placement error, place holder further to the midline and tilt it to make sure teeth are occluding on the bite block.

b.



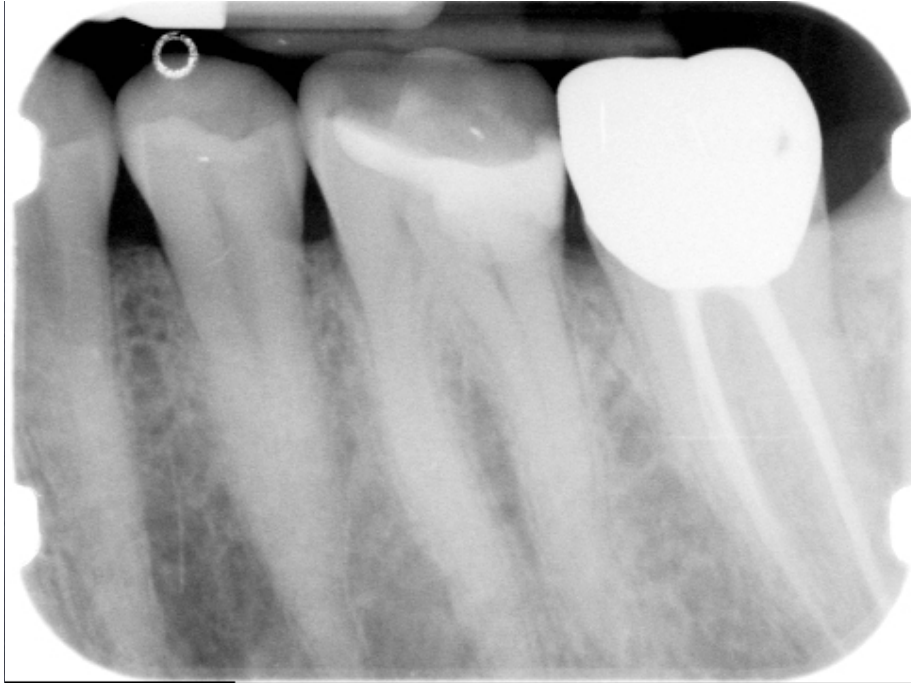Close contacts; horizontal angulation error, Correct horizontal angulation so central ray needs to go perpendicular through the contact

c.



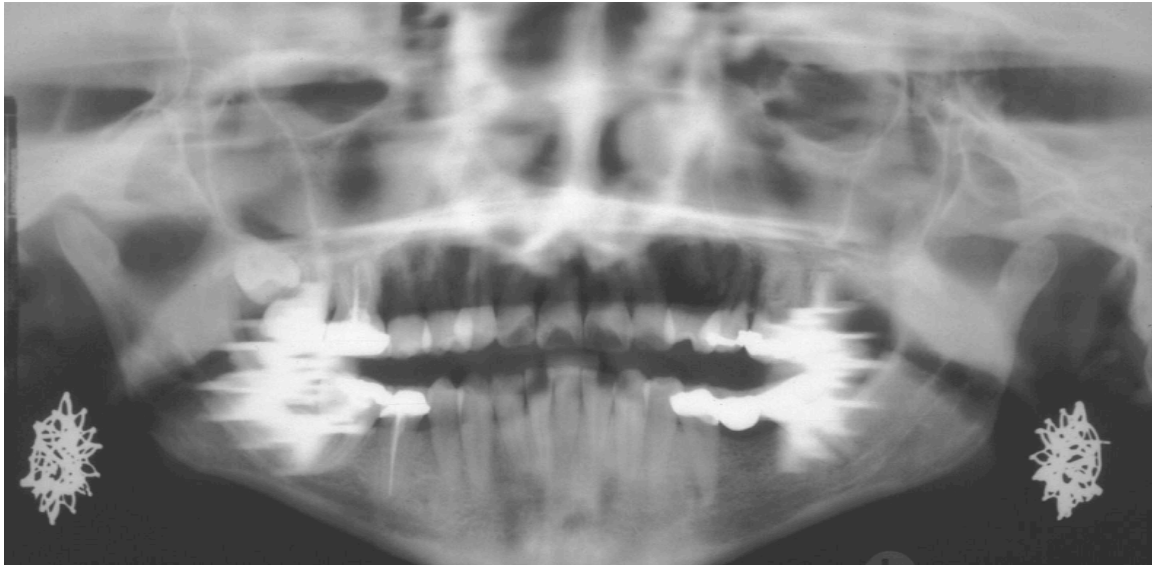Missing pieces of anatomy; Cone cut, align cone to holder better.

d.



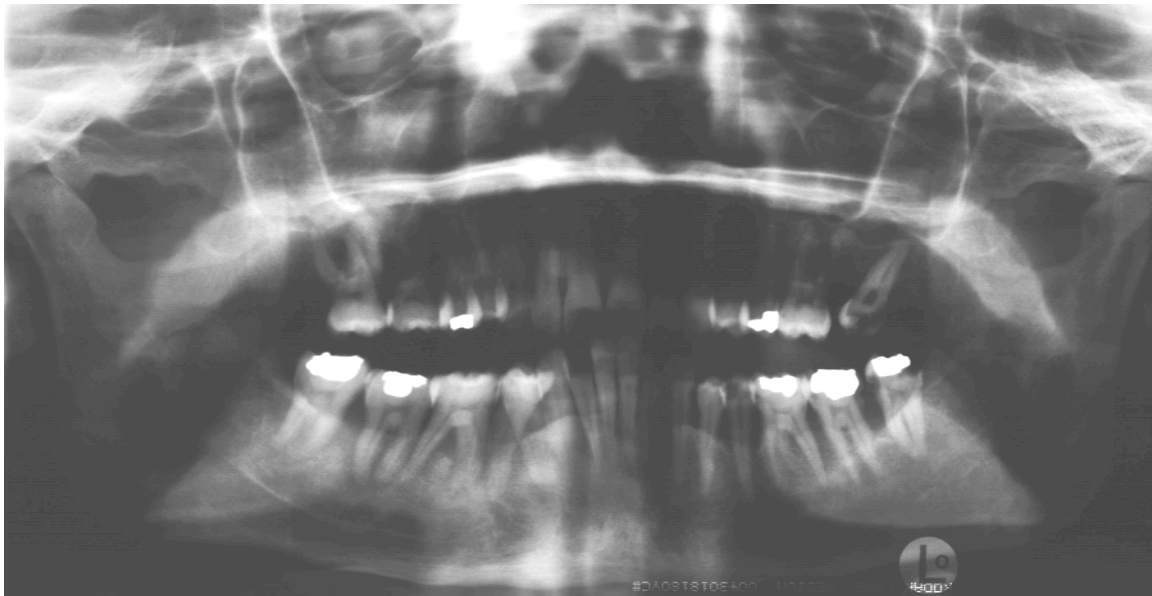Distortion of apical area and elongation of apical part of the roots; film bending, place holder further to the midline to gain more space.

e.



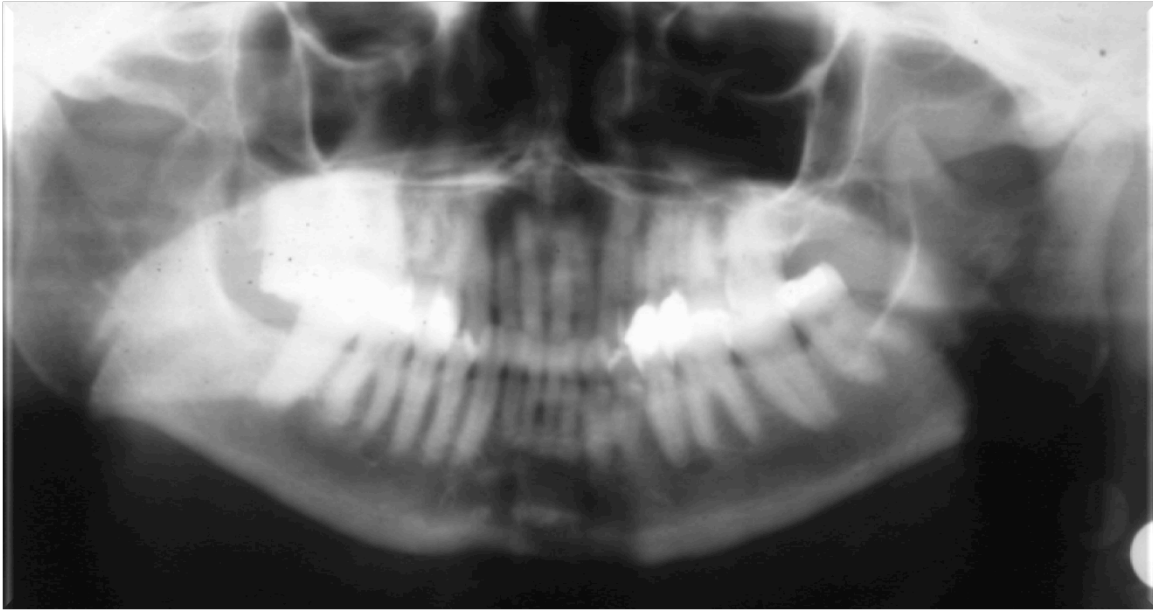
Remaining jewelry creating ghost images, remove patient's jewelry while taking panoramic images.

f.



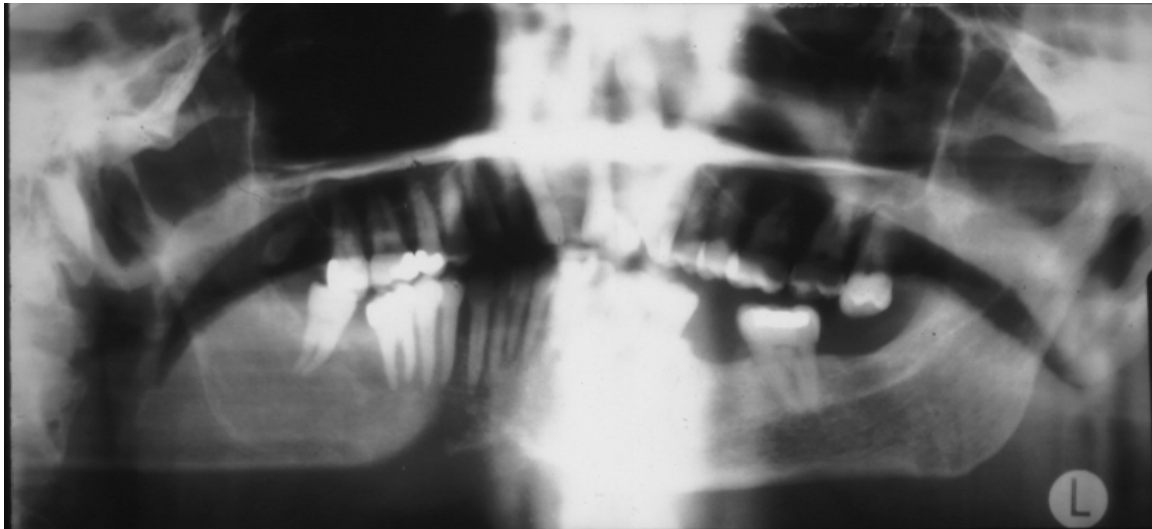
Residual airspace creating an artifact that is covering the apices of maxillary teeth, Patient's tongue needs to be in contact with hard palate while taking the image.

g.



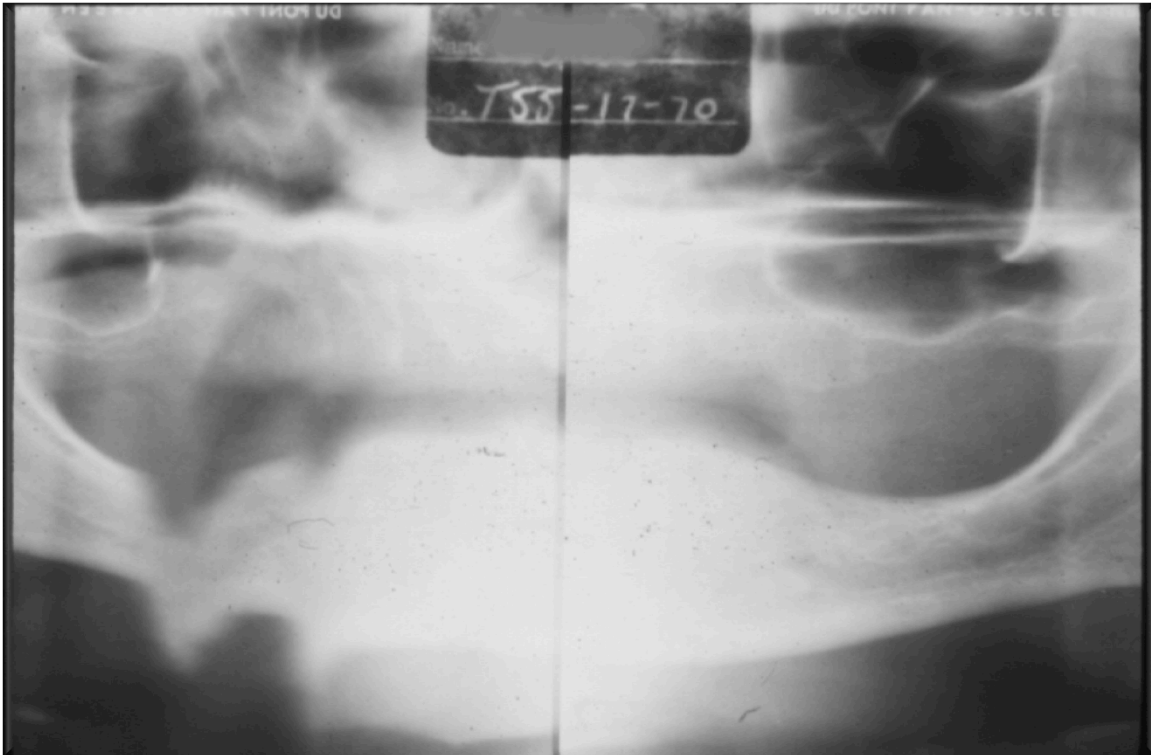Narrow anterior teeth; Patient places too anterior in the machine, place patient in the right anterior-posterior location using a bite block, chin rest, or subnasal contact.

h.



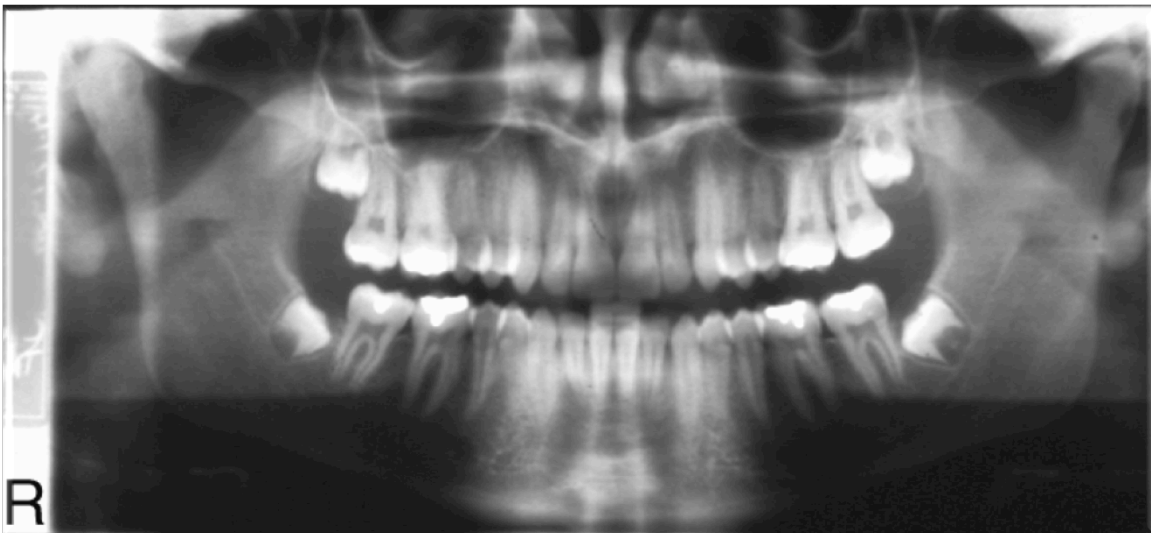
artifacts covering apices of maxillary teeth and a reverse smile line; chin high up, slumped spine and residual airway space, retake correcting aforementioned errors.

i.



Motion artifact; patients needs to stay still while taking a panoramic radiograph.

j.



Good quality panoramic.