



Sunitinib as an anti-endometriotic agent



Manal A. Abbas^{a,*}, Ahmad M. Disi^b, Mutasem O. Taha^c

^a Faculty of Pharmacy, Al-Ahliyya Amman University, Amman 19328, Jordan

^b Department of Biological Sciences, Faculty of Science, The University of Jordan, Amman 11942, Jordan

^c Department of Pharmaceutical Sciences, Faculty of Pharmacy, The University of Jordan, Amman 11942, Jordan

ARTICLE INFO

Article history:

Received 21 February 2013

Received in revised form 16 May 2013

Accepted 24 May 2013

Available online 5 June 2013

Keywords:

Endometriosis

Sunitinib

Rat surgical model

Apoptosis

ABSTRACT

Endometriosis is one of the most frequent diseases in gynecology. Currently available medical therapies for this disease are unsatisfactory. Based on current understanding of the pathogenic mechanisms in endometriosis especially the similarity between this disease and cancer, this study was designed to investigate the efficacy of the anticancer drug sunitinib in treating endometriosis. The effect of sunitinib on regression of endometriotic implants was studied in a rat surgical model. Sunitinib reduced cyst cross sectional area by 78.8% and caused complete cyst disappearance in 50% of the animals. Histologically, extensive fibrosis was detected in sunitinib-treated group with positive reaction in TUNEL assay indicating that apoptosis is a mechanism of action.

© 2013 Elsevier B.V. All rights reserved.

1. Introduction

Endometriosis is one of the most frequent gynaecological diseases (Nothnick and Zhang, 2009). It is defined by the ectopic presence of both endometrial glands and stroma outside the uterus (D'Hooghe et al., 2009). The main side effects of this disease are pain (Story and Kennedy, 2004) and infertility (Matalliotakis et al., 2008).

Despite being a benign disorder, clinical, pathological, molecular and genetic evidences support the hypothesis that endometriosis could be considered as a neoplastic disease with a potential for malignant transformation (Varma et al., 2004). In fact, endometriosis and cancer have common features including: (1) Self-sufficiency in growth signals. It is well established that endometriosis is an estrogen-dependent disease that locally produces estrogen through the increased expression of aromatase cytochrome P450 (Bulun et al., 2000). (2) Insensitivity to anti-proliferative signals: for example endometriosis may resist the antiproliferative action of progesterone by the predominant expression of the inhibitory progesterone receptor (PR-A) isoform instead of the stimulatory PR-B isoform (Attia et al., 2000). (3) Resistance to apoptosis (Meresman et al., 2000). (4) Sustained angiogenesis: pathological angiogenesis exists in both endometriosis and cancer (Folkman, 2002; Gazvani and Templeton, 2002). (5) Tissue invasion and metastasis: According to Borghese et al. (2008), deep endometriosis can invade the surrounding tissues. Furthermore, it may metastasize in lymph nodes and beyond the abdominal cavity.

However, the invasion is controlled in endometriosis since it stops at a given time. So, endometriosis has a unique feature of being a benign metastatic disease (Varma et al., 2004). Even though, some control points prevent endometriotic cells from expressing a more aggressive phenotype (Borghese et al., 2008).

Sunitinib (SU-11248, Sutent; Pfizer) is an oral, multitargeted receptor protein-tyrosine kinase (RTK) inhibitor (Patyna et al., 2008). It has been approved multinationally for the treatment of gastrointestinal stromal tumor after intolerance to or disease progression with imatinib therapy, and for the first-line treatment of advanced renal cell carcinoma (Rock et al., 2007). Clinically, it was also effective in neuroendocrine and breast cancers (Yang et al., 2010). The effectiveness of different tyrosine kinase inhibitors as anti-endometriotic agents was demonstrated (Ngo et al., 2010). So, based on these facts and similarities between endometriosis and cancer, the effect of the anti-cancer drug sunitinib on peritoneal endometriosis was studied after producing it surgically in rats.

2. Materials and methods

2.1. Animals

Animals were treated in accordance with the international guidelines and principles of laboratory animal care (Institute of Laboratory Animal Resources, 1996). Virgin female rats (180–250 g) were obtained from The University of Jordan animal house. At least two-week acclimatization period to the laboratory conditions preceded the use of animals in the experiments. Experimental conditions were as follows: 12 h of light and 12 h of dark,

* Corresponding authors.

E-mail address: manabbas@yahoo.com (M.A. Abbas).

the temperature was maintained between 18 and 25 °C and food and water were provided *ad libitum*. Surgery was performed only to females which exhibited at least 4 regular 4–5 day estrous cycle.

2.2. First surgery: induction of endometriosis

A 3 cm ventral incision was performed under chloralhydrate anesthesia (300 mg/kg, i.p) aseptically. The right uterine horn was resected and the excised horn was immersed in sterile normal saline and the endometrium was exposed by lengthwise incision. Two squares of 4 × 4 mm of open uterus were prepared. Then the two squares were sutured to abdominal muscles with the endometrium facing the peritoneal cavity. The fragment was always fixed over a large blood vessel. A single stitch using 4–0 nylon suture (Hospital & Homecare Imp. & Exp. Co., Ltd., China) was applied at two opposite sides of the uterine fragment. The abdominal wall was closed in two layers using 4/0 nylon suture. Then, two milliliters of sterile normal saline were injected in the abdominal cavity to prevent dehydration and to minimize adhesions.

2.3. Second surgery: measuring cyst length and width

Second surgery was performed 28 days after the first one. The length and width of the implant were measured by a caliper (accuracy = 0.05 mm). Then, the cross sectional area was calculated using the formula for an ellipsoid [$\text{length} \times \text{width} \times (\pi/4)$] (Eltern, 2008). Animals were randomly divided into 3 different groups. Group 1 (9 animals) received 10 mg/kg sunitinib malate (LC labs, USA) dissolved in normal saline. Rats in group 2 (6 animals) received only the vehicle (negative control). Group 3 (7 animals) rats were ovariectomized after measuring cyst dimensions (Chart 1). It is well known that endometriosis is an estrogen-dependent disease. So, in the absence of ovarian estrogen, it is expected that cysts degenerate. Any animal that developed any complications after the first and/or second surgery was excluded. Treatment started immediately after the second surgery by intra-peritoneal injection of the tested compound given once daily and lasted for 21 days.

2.4. Light microscopic studies

At the end of treatment period, endometrial implants (cysts) were excised and stored in 10% formalin solution for histological evaluation. Sections (5 μm) were prepared and stained with haematoxylin and eosin or Masson trichrome stain.

2.5. TUNEL assay

Terminal deoxynucleotidyl transferase-mediated dUTP nick end labeling (TUNEL) assay was performed using the DeadEnd™ Colorimetric TUNEL System from Promega, USA according to the manufacturer's instructions.

2.6. Statistical analysis

The statistical analyses were performed using Statistical Package for Social Sciences (SPSS) version 17. The effect of treatments on cyst regression was evaluated using descriptive analysis.

3. Results

3.1. Regression of endometrial cysts in rats treated with sunitinib

Four weeks after transplantation, the deposit (uterine implant) appeared as a transparent cystic area (Fig. 1) with a fine superficial vascularization. Fat adhesions were very common. Histological examination revealed the presence of endometrial tissue containing stroma and glandular epithelium. In those animals which underwent ovariectomy after cyst development, the cyst disappeared regardless to its original size after 21 days. Ten mg/kg

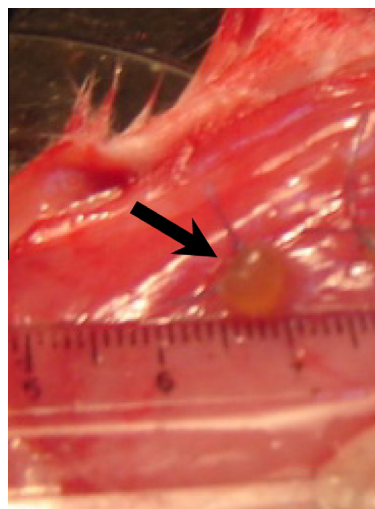


Fig. 1. Growth of endometrial implant into a cystic structure: transparent cyst appeared at the site of transplantation (arrow).

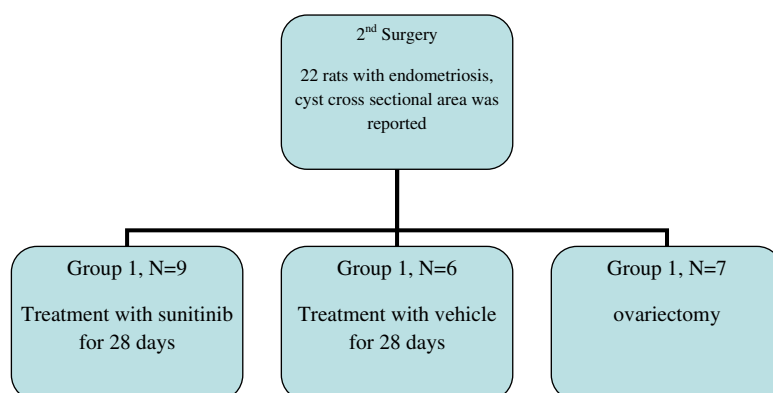
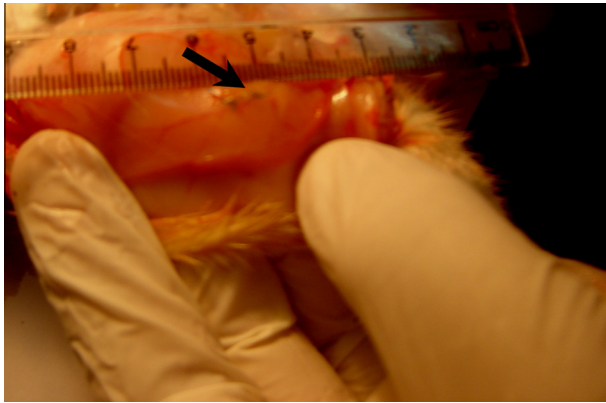
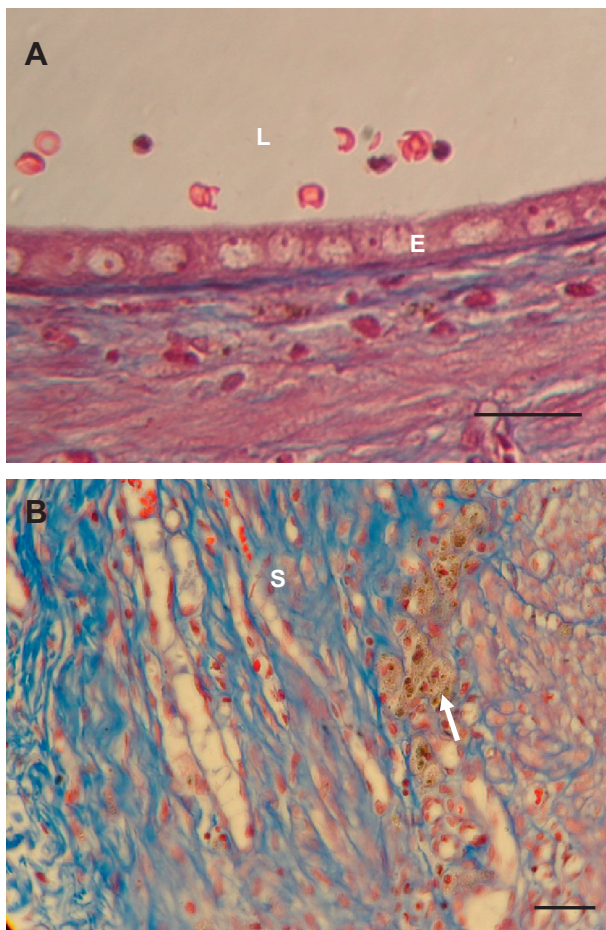


Chart 1. Experimental protocol: In the first surgery, uterine fragments were implanted. In the second surgery the following protocol was followed. While in the third surgery, animals were sacrificed after measuring cyst dimensions.

Table 1Cross-sectional area of the cyst before and after treatment (values are mean \pm SEM).

Treatment	Number of rats/group	Cross sectional area before treatment (mm ²)	Cross sectional area after treatment (mm ²)	Inhibition (%)
Negative control (0.85% NaCl)	N = 6	14.81 \pm 1.66	14.67 \pm 2.06	
Sunitinib (10 mg/kg)	N = 9	13.56 \pm 0.91	2.87 \pm 0.97	78.8
Ovariectomy	N = 7	18.7 \pm 5.3	0 \pm 0	100

**Fig. 2.** Regression of endometrial implants upon treatment with sunitinib: disappearance of the cyst after treatment with sunitinib (arrow).**Fig. 3.** Extensive fibrosis was present within stroma in a sunitinib-treated rat (B) but not in control rat (A). (A) RBC are present in the lumen of the cyst of the control. (B) Hemosiderin is seen (arrow) which is usually present in healed foci of endometriosis (Masson trichrome stain). E: luminal epithelium; L: cyst lumen; S: stroma. Scale bar = 25 μ m in (A) and (B).

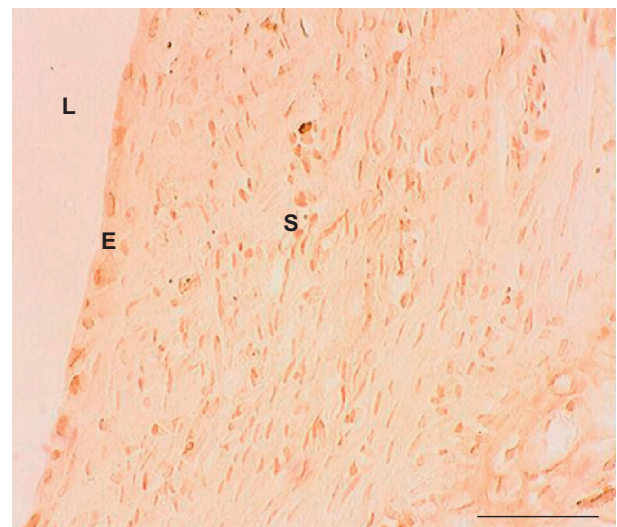
sunitinib given daily for 21 days resulted in 78.8% reduction in cross sectional area of the cyst (Table 1) with complete cyst disappearance in 50% of the animals (Fig. 2). Furthermore, fat adhesions were almost absent. Although many cysts disappeared macroscopically in sunitinib-treated group, they were detected microscopically. However, they were greatly reduced in size. Degenerative changes in luminal epithelium were prominent. Also, extensive fibrosis was observed in the stroma that contained abundant hemosiderin-laden macrophages (Fig. 3).

3.2. Sunitinib produced apoptosis in both luminal epithelium and endothelial cells of blood vessels

Few apoptotic cells in luminal epithelium and stroma were seen in control group (Fig. 4). For sunitinib-treated group, most cells in luminal epithelium were clearly positive in TUNEL assay (Fig. 5). Endothelial cells of blood vessels were positive as well as some cells in stroma (Fig. 6).

4. Discussion and conclusion

Sunitinib (Sutent) is one of the new generation anticancer agents. It is a tyrosine kinase inhibitor with no cytotoxic effects. Its side effects are mild and well tolerated. Adverse events were considered somewhat manageable and the incidence of serious adverse events is low (Demetri et al., 2006). In this study, sunitinib (10 mg/kg) caused complete cyst regression in 50% of the animals with an average reduction in the cross sectional area of the cyst of 78.8%. To the best of our knowledge, this is the first time sunitinib is reported to cause such an effect. In addition to cyst regression, sunitinib reduced fat adhesions. This agrees with the findings of

**Fig. 4.** Results of TUNEL assay-control group. The majority of cells in this section failed to take the dark brown color in TUNEL assay which indicates a negative result for apoptosis E: luminal epithelium; L: cyst lumen; S: stroma. Scale bar = 100 μ m. (For interpretation of the references to color in this figure legend, the reader is referred to the web version of this article.)

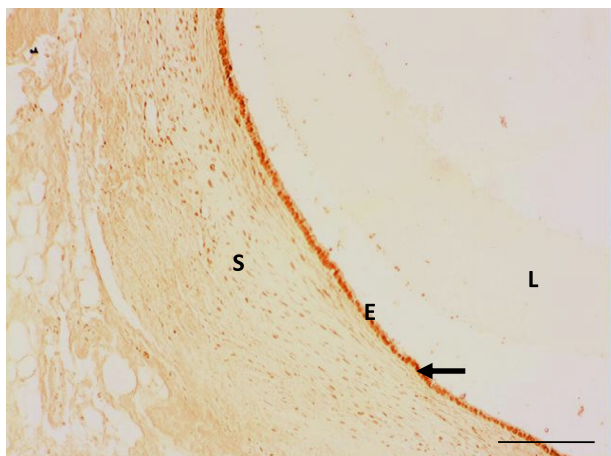


Fig. 5. TUNEL assay for a sunitinib-treated rat. Luminal epithelial cells (black arrow) were positive (dark brown staining) in TUNEL assay as well as few cells in the stroma which means that they underwent apoptosis. E: luminal epithelium; L: cyst lumen; S: stroma. Scale bar = 250 μ m. (For interpretation of the references to color in this figure legend, the reader is referred to the web version of this article.)

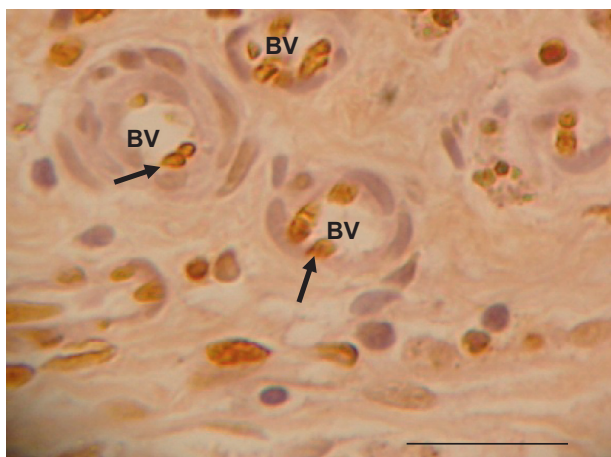


Fig. 6. Positive TUNEL assay for luminal epithelial cells and endothelial cells of blood vessels of a sunitinib-treated rat. Endothelial cells were positive (dark brown staining) in TUNEL assay as well as some cells in the stroma which means that they underwent apoptosis. Sections were counterstained with haematoxylin. BV: blood vessel. E: luminal epithelium; L: cyst lumen; S: stroma. Scale bar = 25 μ m. (For interpretation of the references to color in this figure legend, the reader is referred to the web version of this article.)

Kim et al. (2008) who demonstrated that sunitinib significantly reduces adhesion formation in a murine model.

Several tyrosine kinase inhibitors were studied for their anti-endometriotic effects. For example, imatinib decreased proliferation and transmesothelial migration by endometrial cells in an *in vitro* model (Griffith et al., 2010). Also, it resulted in 35% reduction in number of endometriotic lesions formed in a murine model of endometriosis (Jensen et al., 2008). Similarly, Ngo et al. (2010) provided evidence that protein kinase inhibitors can control endometriotic cell proliferation *in vitro* and endometriosis progression *in vivo*. Treating endometriotic cells with A771726, PD98059 or U0126 significantly decreased cellular proliferation *in vitro*. *In vivo*, A771726, leflunomide, PD98059, and U0126 controlled the growth of endometriotic implants in the mouse model of endometriosis. So, it was suggested that protein kinase inhibitors could be new candidates to treat endometriosis.

It was proposed that inhibition of angiogenesis may lead to regression of endometriotic implants (Onalan et al., 2009).

Sunitinib inhibition of VEGFRs and PDGFRs expressed by vascular or perivascular endothelial cells is predicted to produce anti-angiogenic effects. A recent study by Yao et al. (2006) demonstrated that the dual inhibition of VEGFR and PDGFR with sunitinib is associated with greater antiangiogenic effects compared with selective inhibition of VEGFR or PDGFR alone (Christensen, 2007). In our experiment, sunitinib caused cyst regression after twenty-one days of treatment. It is expected that it caused this regression due, at least in part, to its anti-angiogenic activity. Apoptosis of endothelial cells was evident using TUNEL assay (Fig. 6). According to Baffert et al. (2006), the time course of capillary regression begins within two weeks of treatment, with the loss of vessel patency, intraluminal fibrin deposition, and cessation of blood flow. Apoptosis and the loss of endothelial cells follow (Mancuso et al., 2006).

Acknowledgement

The financial support of the University of Jordan is gratefully acknowledged.

References

- Attia, G.R., Zeitoun, K., Edwards, D., Johns, A., Carr, B.R., Bulun, S.E., 2000. Progesterone receptor isoform A but not B is expressed in endometriosis. *J. Clin. Endocrinol. Metab.* 85, 2897–2902.
- Baffert, F., Le, T., Sennino, B., Thurston, G., Kuo, C.J., Hu-Lowe, D., McDonald, D.M., 2006. Cellular changes in normal blood capillaries undergoing regression after inhibition of VEGF signaling. *Am. J. Physiol. Heart Circ. Physiol.* 290, H547–559.
- Borghese, B., Mondon, F., Noel, J.-C., Fayt, I., Mignot, T.-M., Vaiman, D., Chapron, C., 2008. Gene expression profile for ectopic versus eutopic endometrium provides new insights into endometriosis oncogenic potential. *Mol. Endocrinol.* 22 (11), 2557–2562.
- Bulun, S.E., Zeitoun, K.M., Takayama, K., Sasano, H., 2000. Estrogen biosynthesis in endometriosis: molecular basis and clinical relevance. *J. Mol. Endocrinol.* 25, 35–42.
- Christensen, J.G., 2007. A preclinical review of sunitinib, a multitargeted receptor tyrosine kinase inhibitor with anti-angiogenic and antitumour activities. *Ann. Oncol.* 18 (Supplement 10), x3–x10.
- Demetri, G.D., van Oosterom, A.T., Garrett, C.R., Blackstein, M.E., Shah, M.H., Verweij, J., McArthur, G., Judson, I.R., Heinrich, M.C., Morgan, J.A., Desai, J., Fletcher, C.D., George, S., Bello, C.L., Huang, X., Baum, C.M., Casali, P.G., 2006. Efficacy and safety of sunitinib in patients with advanced gastrointestinal stromal tumour after failure of imatinib: a randomised controlled trial. *Lancet* 368 (9544), 1329–1338.
- D'Hooghe, T.M., Kyama, C.K., Mwenda, J.M., 2009. Baboon model for endometriosis. In: VandeBerg, J.L. (Ed.), *The Baboon in Biomedical Research*. Springer Science and Business Media LLC, pp. 139–156.
- Eltorn, M., 2008. Development and evaluation of two mouse models for endometriosis focused on the involvement of the immune system in endometriosis establishment, PhD Thesis, University of Berlin.
- Folkman, J., 2002. Role of angiogenesis in tumor growth and metastasis. *Semin. Oncol.* 29 (Supplement 16), 15–18.
- Gazvani, R., Templeton, A., 2002. Peritoneal environment, cytokines and angiogenesis in the pathophysiology of endometriosis. *Reproduction* 123, 217–226.
- Griffith, J.S., Binkley, P.A., Kirma, N.B., Schenken, R.S., Witz, C.A., Tekmal, R.R., 2010. Imatinib decreases endometrial stromal cell transmesothelial migration and proliferation in the extracellular matrix of modeled peritoneum. *Fertil. Steril.* 94 (7), 2531–2535.
- Jensen, J.R., Witz, C.A., Schenken, R.S., Tekmal, R.R., 2008. Imatinib decreases the rate of early endometriotic lesion formation in a murine model. *Fertil. Steril.* 90 (Supplement 1), S142–S143.
- Kim, S., Lee, S., Greene, A.K., Arsenault, D.A., Le, H., Meisel, J., Novak, K., Evelyn Flynn, E., Heymach, J.V., Puder, M., 2008. Inhibition of intra-abdominal adhesion formation with the angiogenesis inhibitor sunitinib. *J. Surg. Res.* 149, 115–119.
- Mancuso, M.R., Davis, R., Norberg, S.M., O'Brien, S., Sennino, B., Nakahara, T., Yao, V.J., Inai, T., Brooks, P., Freimark, B., Shalinsky, D.R., Hu-Lowe, D.D., McDonald, D.M., 2006. Rapid vascular regrowth in tumors after reversal of VEGF inhibition. *J. Clin. Invest.* 116, 2610–2621.
- Matalliotakis, I.M., Cakmak, H., Fragouli, Y.G., Goumenou, A.G., Mahutte, N.G., Arici, A., 2008. Epidemiological characteristics in women with and without endometriosis in the Yale series. *Arch. Gynecol. Obstet.* 277, 389–393.
- Meresman, G.F., Vighi, S., Buquet, R.A., Contreras-Ortiz, O., Tesone, M., Rumi, L.S., 2000. Apoptosis and expression of bcl-2 and bax in eutopic endometrium from women with endometriosis. *Fertil. Steril.* 74, 760–766.
- Ngo, C., Nicco, C., Leconte, M., Chereau, C., Arkwright, S., 2010. Protein kinase inhibitors can control the progression of endometriosis *in vitro* and *in vivo*. *J. Pathol.* 222, 148–157.

- Nothnick, W.B., Zhang, X., 2009. Future targets in endometriosis treatment: targeting the endometriotic implant. *Mini-Rev. Med. Chem.* 9, 324–328.
- Onalan, G., Zeyneloglu, H.B., Nilufer Bayraktar, N., 2009. Fenofibrate causes regression of endometriotic implants, a rat model. *Fertil. Steril.* 92 (6), 2100–2102.
- Patyna, S., Arrigoni, C., Terron, A., Kim, T.-W., Heward, J.K., Vonderfecht, S.L., Denlinger, R., Turnquist, S.E., Evering, W., 2008. Nonclinical safety evaluation of sunitinib, a potent inhibitor of VEGF, PDGF, KIT, FLT3, and RET receptors. *Toxicol. Pathol.* 36, 905–916.
- Rock, E.P., Goodman, V., Jiang, J.X., Mahjoob, K., Verbois, S.L., Morse, D., Dagher, R., Justice, R., Pazdur, R., 2007. Food and drug administration drug approval summary, sunitinib malate for the treatment of gastrointestinal stromal tumor and advanced renal cell carcinoma. *Oncologist* 12, 107–113.
- Story, L., Kennedy, S., 2004. Animal studies in endometriosis: a review. *ILARJ* 45 (2), 132–138.
- Varma, R., Rollason, T., Gupta, J.K., Maher, E.R., 2004. Endometriosis and the neoplastic process. *Reproduction* 127, 293–304.
- Yang, F., Jove, V., Xin, H., Hedvat, M., Van Meter, T.E., HuaYu, H., 2010. Sunitinib induces apoptosis and growth arrest of medulloblastoma tumor cells by inhibiting STAT3 and AKT signaling pathways. *Mol. Cancer Res.* 8 (1), 35–45.
- Yao, V.J., Sennino, B., Davis, R.B., 2006. Combined anti-VEGFR and anti-PDGFR actions of sunitinib on blood vessels in preclinical tumor models. In: Presented at the 18th EORTC–NCI–AACR Symposium, Prague, Czech Republic, 7–10 November 2006.