



ELSEVIER

Contents lists available at SciVerse ScienceDirect

European Journal of Pharmacology

journal homepage: www.elsevier.com/locate/ejphar

Endocrine pharmacology

β -Caryophyllene causes regression of endometrial implants in a rat model of endometriosis without affecting fertility

Manal A. Abbas^a, Mutasem O. Taha^b, Malek A. Zihlif^c, Ahmad M. Disi^{d,*}^a Faculty of Pharmacy, Al-Ahliyya Amman University, Amman 19328, Jordan^b Department of Pharmaceutical Sciences, Faculty of Pharmacy, The University of Jordan, Amman 11942, Jordan^c Department of Pharmacology, Faculty of Medicine, The University of Jordan, Amman 11942, Jordan^d Department of Biological Sciences, Faculty of Science, The University of Jordan, Amman 11942, Jordan

ARTICLE INFO

Article history:

Received 2 August 2012

Received in revised form

22 December 2012

Accepted 15 January 2013

Available online 23 January 2013

Keywords:

 β -Caryophyllene

Rat surgical model

Aortic ring assay

Endometriosis

Ultrastructure

ABSTRACT

Many studies have shown that anti-inflammatory agents are effective in the treatment of endometriosis. β -Caryophyllene exerted a potent anti-inflammatory effect *in vivo*. However, its effect on endometriosis has not been investigated. This study aims at investigating the effect of β -caryophyllene on endometriosis and on fertility and reproduction in adult female rats. Autologous fragments of the endometrium were implanted in the peritoneal cavity in adult female rats. The growth of the endometriotic implants that developed after four weeks was recorded. Treatment started then with β -caryophyllene (10 mg/kg or 30 mg/kg) or vehicle (control) for 21 days and the growth of the endometriotic implants was measured again. In fertility studies, female rats that received β -caryophyllene or vehicle were mated and reproductive functions were observed including number and viability of implants, number of corpora lutea, length of pregnancy and outcome of litter. β -Caryophyllene (10 mg/kg) suppressed the growth of endometriotic implants by 52.5% compared with controls. Also β -caryophyllene produced apoptosis in luminal epithelium of the cyst as well as in endothelial cells of blood vessels. Ultrastructural studies revealed the presence of active mast cells and eosinophils in both control and β -caryophyllene-treated rat cysts. No statistically significant difference was observed in any studied parameter between control and β -caryophyllene-treated groups in fertility study. Therapy with β -caryophyllene may present a promising novel, non-toxic therapeutic option for patients with endometriosis.

© 2013 Published by Elsevier B.V.

1. Introduction

Endometriosis is a benign gynecologic disease defined by the ectopic presence of both endometrial glands and stroma (D'Hooghe et al., 2009). It is one of the most frequent diseases in gynecology affecting 5–15% of women in the reproductive stage of their life (Nothnick and Zhang, 2009). Endometriosis is most commonly found in the peritoneum, ovaries and rectovaginal septum (Agic et al., 2009). Symptoms of the disease include pelvic dysmenorrhea (painful menstrual periods), noncyclical pelvic pain, dyspareunia (pain on intercourse), dyschezia (pain during defaecation) and infertility (Story and Kennedy, 2004). Despite the high incidence of endometriosis, our understanding of the pathophysiology of this disease remains obscure (Agic et al., 2009). Moreover, currently available medical therapies are unsatisfactory because they focus on treating the symptoms rather than curing the causes. In addition, they cannot be used for prolonged duration because of severe side effects (Rice, 2002) and because they compromise fertility (Panay, 2008).

β -Caryophyllene is a major volatile compound found in large quantities in the essential oil of *Cannabis sativa* L. (up to 35%) (Hendriks et al., 1975). Also, it is common in different spice and food plants, such as oregano (*Origanum vulgare* L.) (Mockute et al., 2001), cinnamon (*Cinnamomum* spp.) (Jayaprakasha et al., 2003), *Eugenia caryophyllata* (Zheng et al., 1992), *Zingiber nimmonii* (Sabulal et al., 2006) and black pepper (*Piper nigrum* L.) (Orav et al., 2004). β -Caryophyllene has shown to possess potent anti-inflammatory properties (Fernandes et al., 2007; Gertsch, 2008). Using animal models of endometriosis, many studies have shown that anti-inflammatory agents are effective in the treatment of this disease (Dogan et al., 2004; Ozawa et al., 2006). Based on these facts, this study was designed to investigate the effect of β -Caryophyllene on endometriosis as well as on fertility and reproduction.

2. Materials and methods

2.1. Animals

Animals under experimental work were handled and treated in a humane manner in accordance with the Declaration of

* Corresponding author. Tel.: +962 777424331.

E-mail address: ahmadmdisi@yahoo.com (A.M. Disi).

Helsinki. Virgin female rats (180–250 g) were obtained from The University of Jordan animal house. At least two-week acclimatization period to the laboratory conditions preceded the use of animals in the experiments. Experimental conditions were as follows: 12 h of light and 12 h of dark, the temperature was maintained between 18 and 25 °C and food and water were provided *ad libitum*.

2.2. Vaginal cytology

Vaginal smears were prepared as in Marcondes et al. (2002) with some modifications. Briefly, smears were taken daily between 10:00 a.m. and 1:00 p.m. Vaginal secretion was collected with a micropipette filled with about 100 µl of normal saline by inserting the tip into the rat vagina. The collected vaginal fluid was examined under a light microscope without staining using medium power objective lens. The phase of the estrous cycle was determined as follows: estrus is characterized by the presence of cornified epithelial cells, metestrus attained similar proportions among leukocytes, cornified, and nucleated epithelial cells, diestrus by predominance of leukocytes cells and proestrus by predominance of nucleated epithelial cells. Only those females which exhibited at least four regular 4–5 day estrous cycle underwent surgery.

2.3. Chemicals

The following chemicals were purchased from Sigma-Aldrich, USA: β -caryophyllene (purity $\geq 98.5\%$), Aprotinin, from bovine lung (lyophilized), thrombin from bovine plasma (lyophilized), 6-aminocaproic acid, gentamicin solution (suitable for cell culture), dimethylsulfoxide, for molecular biology (purity $\geq 99.9\%$), suramin sodium salt (purity $\geq 95\%$), phosphate buffer saline and L-glutamine. Chloralhydrate was obtained from Medical Export Co Ltd, UK, Amphotericin B from PAA-The Cell Culture Company, USA, fibrinogen from bovine plasma from calbiochem, USA, fetal Bovine Serum (EU Approved Origin) from Gibco, USA, medium 199 powder (10 × 1 L) - with Earle's salt & L-glutamine, without sodium bicarbonate- Gibco, USA-Bio Diagnostics Sdn. Bhd. Tissue Culture multi-dish 48 wells were purchased from Nunclon surface Corning, USA-FC Bios Sdn Bhd.

2.4. First surgery: induction of endometriosis

The technique of Vernon and Wilson (1985) was used with the following modifications. Briefly, a 3 cm ventral incision was performed under chloralhydrate anesthesia (300 mg/kg, i.p.) aseptically. The right uterine horn was resected using 4–0 nylon suture (Hospital & Homecare Imp. & Exp. Co., Ltd., China) and the excised horn was immersed in sterile normal saline and the endometrium was exposed by lengthwise incision. Two squares of 4 × 4 mm of open uterus were prepared. Then the two squares were sutured to abdominal muscles with the endometrium facing the peritoneal cavity. The uterine fragment was fixed over a large blood vessel using two stitches with 4–0 nylon suture. The abdominal wall was closed in two layers using 4/0 nylon suture. Then, 2 ml of sterile normal saline were injected in the abdominal cavity to prevent dehydration and to minimize adhesions.

2.5. Second surgery: measuring cyst length and width

All animals underwent second surgery 28 days after the first one. The length and width of the implant were measured by a caliper (accuracy=0.05 mm). Then, the cross sectional area was calculated using the formula for an ellipsoid [length × width × ($\pi/4$)] (Eltern, 2008). Animals were randomly divided into different groups. Group 1

(N=8) received β -caryophyllene (10 mg/kg in 2.5% tween 20), group 2 (N=9) received β -caryophyllene 30 mg/kg in 2.5% tween 20 and group 3 (N=10) received only the vehicle under diethyl ether anesthesia. Since the oral LD₅₀ of β -caryophyllene in rat is more than 5000 mg/kg (Hart and Wong, 1971), then the two doses used in this study of β -caryophyllene were chosen to be less than 1/100 of that LD₅₀ taking into consideration the sub-chronic period of treatment and the route of administration in this study (i.p). The selected doses (10 mg/kg and 30 mg/kg) were based on previously conducted pilot studies. Group 4 (N=7) rats were ovariectomized after measuring cyst dimensions. Any animal that developed any complications (severe weight loss, wound infection, ...) after the first and/or second surgery was excluded. Treatment started immediately after the second surgery by intra-peritoneal injection of the tested compound given once daily and lasted for 21 days.

At the end of treatment period, endometrial explants (cysts) were excised and stored in 10% formalin solution for histological evaluation. Sections (5 µm) were prepared and stained with haematoxylin and eosin. Sections (5 µm) were stained with Masson trichrome stain to detect fibrosis (if present). Stroma scoring was performed by scoring 5 high power field (hpf) (400 ×) and the average of them was calculated. Histological score 0 was given if the percentage of the hpf containing stroma tissue was zero, 1 if it was < 25, 2 if stroma forms 25–50% of the hpf and 4 if it was > 50. Furthermore, sections (5 µm) were stained with toluidine blue stain for staining of mast cells. Sections were then examined by a light microscope. For mast cell degranulation, all mast cells in the section within cyst area were examined and classified as degranulated or non-degranulated depending on the presence of granules outside and close to the cells. The percentage of degranulation was then calculated.

For electron microscopic studies, specimens were fixed in Karnovsky fixative (Karnovsky, 1965), embedded in Spurr's medium, cut into 70–90 nm thick silver gold sections with ultracut E Reichert Tung ultramicrotome and stained with aqueous uranyl acetate (30 min)/Renyold's lead citrate (15 min) and viewed using Zeiss electron microscope 10 CR/Yarmouk University.

2.6. TUNEL assay

Terminal deoxynucleotidyl transferase-mediated dUTP nick end labeling (TUNEL) assay was performed using the DeadEnd™ Colorimetric TUNEL System from Promega, USA according to the manufacturer's instructions.

2.7. Anti-angiogenic effect of β -caryophyllene (aortic ring assay)

The assay was performed according to the standard protocol of Brown et al. (1996). Briefly, male rats (250 g) were humanely sacrificed by cervical dislocation under ether anesthesia. Thoracic aorta was excised and cleaned from the fibroadipose tissue and from blood. Then, it was rinsed with serum free medium and was cross sectioned into 1–2 mm thick rings. *Preparation of tissue culture:* Medium of the lower layer was prepared by adding fibrinogen and aprotinin to M199 basal medium at 3 mg/ml and 5 µg/ml, respectively. A 300 µl of M199 medium were loaded into each well of a 48-well plate and one aortic ring was seeded. Then, 10 µl thrombin were added to each well. This medium was incubated for 1 h in 5% CO₂ incubator for 2 h at 37 °C. After gel formation, each well was covered with 1 ml M199 medium supplemented with 20% fetal bovine serum, 0.1% aminocaproic acid, 1% L-glutamine (2 mM), 0.6% gentamycin and 1% amphotericin B. Then caryophyllene (1 µM, 10 µM or 100 µM) were added. Each concentration of the tested compound was applied into four wells. The plate was incubated again at 37 °C in 5% CO₂ humidified incubator. On day 4, the upper layer of the medium was

changed. Cultures were observed twice weekly with an inverted microscope for any sprouting of capillaries as an evidence of angiogenesis. Dimethylsulfoxide (DMSO) was used as a negative control as it was used as a solvent for caryophyllene. Suramin (100 µg/ml) served as a positive control.

Quantification of the blood vessel outgrowth: The magnitude of blood vessel outgrowth was quantified according to the method of Nicosia et al. (1997). Briefly, the distance of blood vessels outgrowing from the primary tissue explants was measured on day 8 using inverted light microscope ($4\times$). For vessel quantification, Leica Quin software package was used. The growth distance of at least 20 blood vessels per ring was measured. Blood vessels were selected at regular intervals around the rings to reduce the bias. The results were presented as mean \pm S.D. The following formula was used to calculate the percentage of inhibition:

$$\text{Percent of blood vessel inhibition} = (1 - (A_o/A)) \times 100\%$$

where

A_o = distance of blood vessel growth in the sample.

A = distance of blood vessel growth in the control.

2.8. Effect of β -caryophyllene on fertility

In all fertility experiments, no endometriosis was induced in any animal to exclude the possibility of interference with fertility. Female rats with at least four regular estrous cycles and in proestrus stage were placed with males, with proven fertility, over night in wire floor mating cages. Mating was monogamous. No synchronization of the estrous cycle was performed among females. Every morning during the mating period, each female was examined for the presence of vaginal plugs or sperm in vaginal smears as evidence of mating and the day of their occurrence was designated as day 1 of pregnancy. After mating, females were randomly divided into 6–8 rats per group to receive either caryophyllene 50 mg/kg or vehicle intraperitoneally.

2.8.1. Effect of β -caryophyllene on ovulation

Each virgin female rat received 50 mg/kg β -caryophyllene in 2.5% tween i.p for 3 consecutive days starting from days 3 to 1 (1/100 of the oral LD₅₀ of β -caryophyllene taking into consideration the route of administration in this study (i.p)). The second group (control) received vehicle in a similar way. Then, sexually mature females (160–165 g) were mated with adult males. On day 10, rats were sacrificed. Day 10 was chosen because the fetuses are big enough to be visually counted. The implantation sites and resorption sites (after staining with 10% ammonium sulfide) were counted grossly using dissecting microscope by a person blinded to the treatments.

2.8.2. Effect of β -caryophyllene on implantation

Sexually mature mated females weighing 160–165 g were randomly divided into two groups. In the first group, each pregnant rat received 0.9 ml of 50 mg/kg β -caryophyllene emulsified in 2.5% tween 20 i.p for 3 consecutive days starting from days 3 to 5 of gestation (as in Hijazi and Salhab, 2010; Sookvanichsilp and Pulbutr, 2002). The second group (control) received 0.9 ml vehicle in a similar way. On day 10, rats were authenticated. The fetuses and resorption sites (after staining with 10% ammonium sulfide) counted grossly using dissecting microscope by a person blinded to the treatments.

2.8.3. Effect of β -caryophyllene on mid-gestation

Each female rat (200–280 g) received i.p. injection of β -caryophyllene (50 mg/kg in 2.5% tween 20) or vehicle for three consecutive

days (day 13–15 of gestation) as in Al-Dissi et al. (2001). Rats were authenticated on day 16 under ether anesthesia. Fetuses were collected, counted and weighed.

2.8.4. Effect of β -caryophyllene on late-gestation

Pregnant rats (200–280 gm) on day 18 of gestations received intraperitoneally a daily dose of 50 mg/kg β -caryophyllene for 3 consecutive days as in. The second group (control) received vehicle in a similar way. On day 21 of gestation females were authenticated. The viability (tested by the presence of reflex motion after touching the fetus with forceps as in Couri et al., 1982) and the numbers of corpora (after staining with 10% ammonium sulfide) for each ovary were counted by a person blinded to the treatments.

2.8.5. Effect of β -caryophyllene on normal delivery

Pregnant rats (200–280 g) on day 18 of gestations were randomly divided into two groups. Each pregnant rat received intraperitoneally a daily dose of 50 mg/kg β -caryophyllene or vehicle for 3 consecutive days starting from days 18 to 20 of gestation. Females were allowed to deliver spontaneously. Number of pups, their weight and the day of delivery was recorded by a person blinded to the treatments.

2.9. Statistical analysis

The statistical analyses were performed using Statistical Package for Social Sciences (SPSS) version 17. The effect of treatments on cyst regression was evaluated by one-way analysis of covariance (ANCOVA) using Sidak corrected *post hoc* comparisons. For aortic ring assay, and mast cell degranulation one-way analysis of variance (ANOVA) was used followed by least significant difference (LSD) analysis. As the distribution of the pathological scores of stroma was found not to be normal, the Kruskal–Wallis test for non-parametric analysis was used followed by Mann–Whitney test. For fertility studies, independent-t test was performed to compare control and caryophyllene-treated groups. In all tests a P value < 0.05 was considered significant.

3. Results

3.1. Effect of β -caryophyllene on regression of endometrial explants

Four weeks after transplantation, the deposit appeared as a transparent cystic area. Histological examination revealed the presence of endometrial tissue containing stroma and glandular epithelium (Fig. 1A, B). In those animals which underwent ovariectomy after cyst development, the cyst disappeared regardless to its original size after 21 days. No animal died during treatment. β -Caryophyllene (10 mg/kg) produced 52.5% regression in cyst surface area while 30 mg/kg dose produced 40.6% regression (Table 1).

3.2. Histological findings

In those animals which received vehicle as the only treatment, glandular tissue was present within stroma (Fig. 1A). The stroma was highly vascularized, heavily infiltrated with inflammatory cells. Also, the epithelial layer was well-preserved (Fig. 1B). In addition, inflammatory cells were sometimes present within cyst lumen and the lumen of glandular tissue. In β -caryophyllene-treated group, cyst was still present but reduced in size (Table 1). Glandular tissue within stroma was almost absent in most specimens (Fig. 1C). In ovariectomized rats, degenerative changes within glandular tissue – if present – were evident (Fig. 2).

Masson trichrome stain revealed that fibrosis was mild and focal in cyst stroma of β -caryophyllene-treated rats compared to

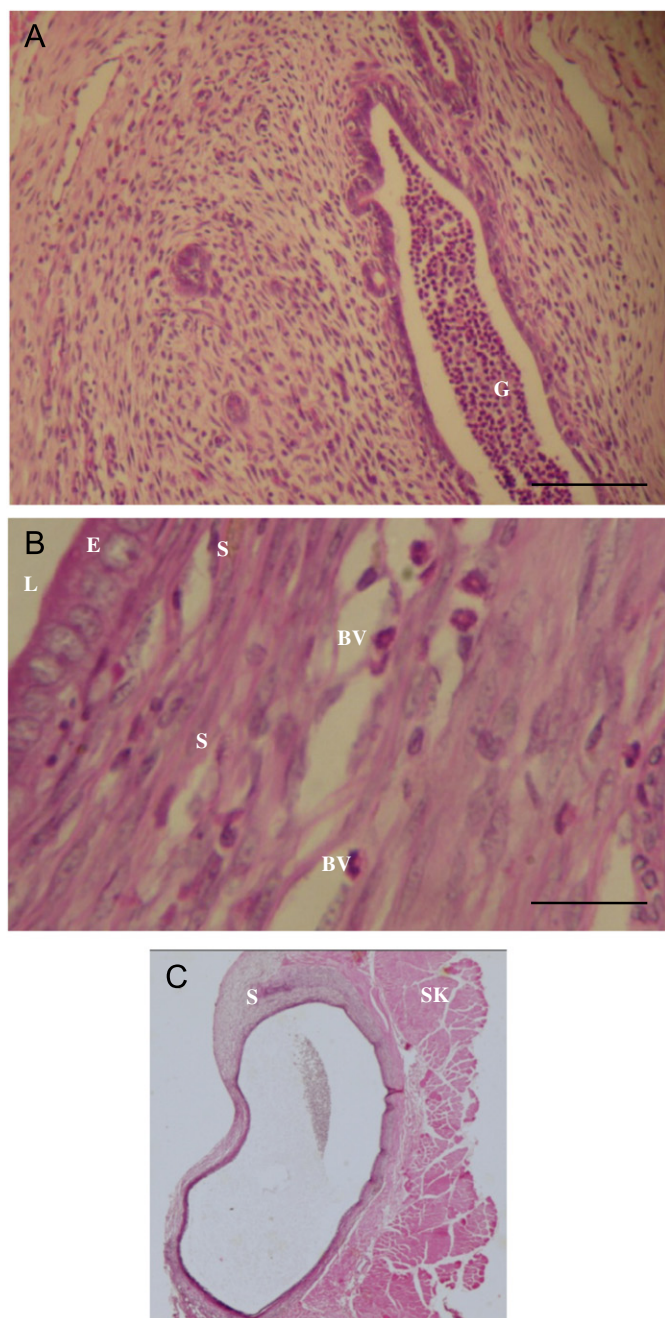


Fig. 1. Light microscopic picture of a control and β -caryophyllene-treated rat cysts. (A) A cyst of a control rat showing that the stroma contains glandular tissue rich with inflammatory cells in its lumen. (B) Luminal epithelium was well preserved in the control-group. The stroma was highly vascularized. (C) A cyst of a β -caryophyllene-treated rat. In this section, cyst is still present but glandular tissue was not seen within stroma. Note the presence of inflammatory cells within cyst lumen (H&E stain). BV, blood vessel; E, luminal epithelium; G, glandular tissue; L, cyst lumen; S, stroma; SK, skeletal muscles. Scale bar=100 μ m in A; 25 μ m in B, 1000 μ m in C.

the vehicle-treated control. Histological scores were 2.7 ± 0.3 for vehicle-treated control group and 1.9 ± 0.5 , 1.6 ± 0.6 for the group that received 30 mg/kg and 10 mg/kg β -caryophyllene, respectively which were statistically significant ($P < 0.05$). No statistically significant difference in the percentage of degranulation of mast cells was observed between the negative control group (56.8 ± 8.7) and β -caryophyllene-treated group (56.9 ± 8.6).

TUNEL assay of cysts of β -caryophyllene-treated group revealed that most cells in the endometrial lining were positive as indicated by

Table 1
Cross sectional area of the cyst before and after treatment.

Treatment	Cross sectional area before treatment (mm^2)	Cross sectional area after treatment (mm^2)	Percentage reduction
β -Caryophyllene (10 mg/kg)	13.9 ± 1.1	6.6 ± 0.6	52.5 ^a
β -Caryophyllene (30 mg/kg)	12.2 ± 1.5	7.2 ± 1.6	41.0 ^a
Negative control (2.5% tween 20)	11.8 ± 1.6	11.5 ± 1.5	2.5

Values are Mean \pm S.E.M.

^a Statistically significant difference from the control, $P < 0.05$

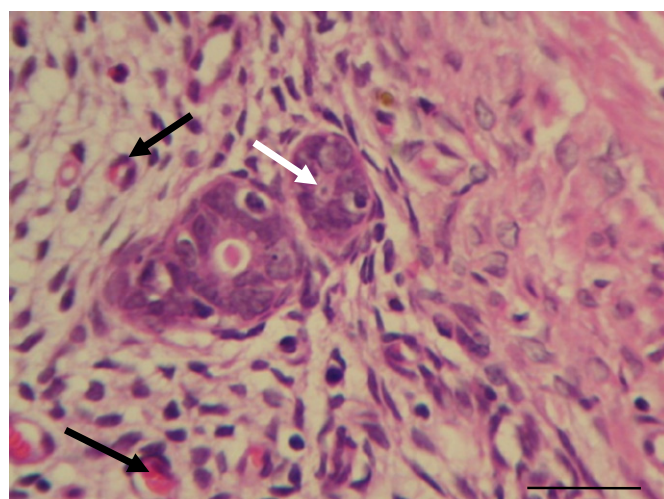


Fig. 2. Light microscopic picture of an ovariectomized rat cyst. Degenerative changes within glandular tissue (white arrow) were evident. Note the high number of blood vessels around the glandular tissue (black arrows) (H&E stain). Scale bar=25 μ m.

the staining of their nuclei with brown color (Fig. 3A). Few cells in the stroma were positive. Interestingly, endothelial lining of small blood vessels was positive as well (Fig. 3B).

Ultrastructure studies revealed that mast cells of the negative control (rats received vehicle only) and β -caryophyllene-treated groups were active as deduced from the reduced electron density of some of their granules (Figs. 4A and 5). Also, granules do existed outside the cells as in Fig. 4B. Furthermore, a perigranular space separating the perigranular membrane from the granule matrix was observed (Fig. 5). This, most probably, will be followed with fusion with the cell membrane.

Signs of eosinophilic activity in both control and β -caryophyllene-treated rat cysts were noticed like the presence of crystals with low electron density cores (Fig. 4A). Also, cytolysis of some eosinophils in β -caryophyllene-treated rats was observed.

3.3. Anti-angiogenic effect

Results of aortic ring assay are shown in Table 2. Neither 1 μ M nor 10 μ M were able to inhibit growth of capillaries. However, a 51% inhibition was achieved using 100 μ M concentration.

3.4. Effect of β -caryophyllene on fertility

No statistically significant difference was reported for the effect of β -caryophyllene on ovulation and implantation. In

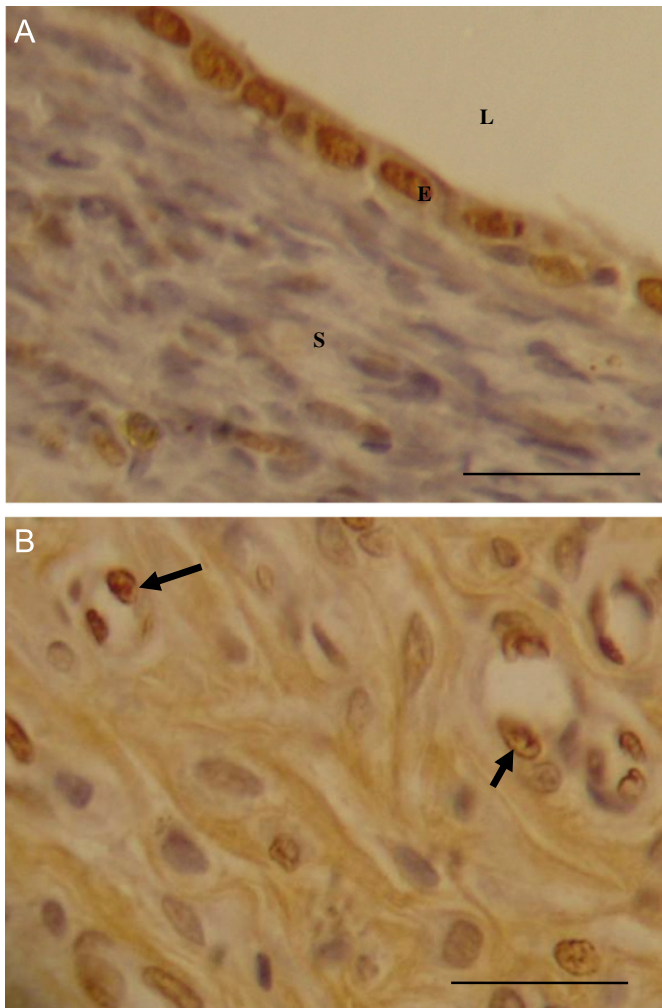


Fig. 3. (Colour online) TUNEL assay for a cyst of a β -caryophyllene-treated rat. Brown color of nuclei (dark nuclei) indicates the presence of apoptosis (arrow) while violet nuclei are not apoptotic. Note the presence of extensive apoptosis in luminal epithelium in A and the presence of apoptosis in endothelial cells of some blood capillaries in B (arrow). Sections were counterstained with haematoxylin. E: luminal epithelium; L: cyst lumen; S: stroma. Scale bar=25 μ m in A & B.

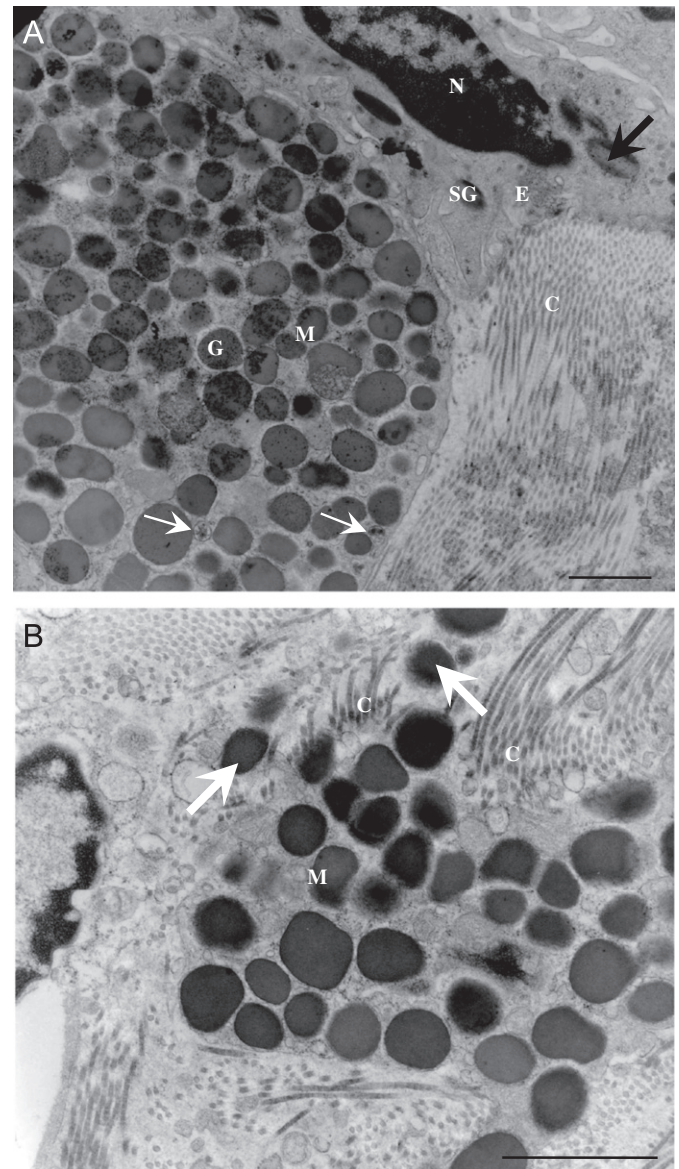


Fig. 4. Electron micrograph of mast cells in control group. (A) This image shows a mast cell and an eosinophil of a control group. Mast cell granules showed variable electron densities. Small vesicles containing electron-dense material were seen (white arrows). Some granules in the eosinophil contained light crystals (black arrow). (B) Electron micrograph of a degranulating mast cell of a control rat. In this electron micrograph a part of a mast cell is seen with granules showing variable electron densities. Note the presence of some granules outside the cell (arrows) which indicates secretory activity of these cells. C, collagen fibers; E, eosinophil; G, granule; M, mast cells; N, nucleus; SG, specific granules. Scale bar=1.05 μ m in A; 1.25 μ m in B.

ovulation experiment, number of implant sites was 10.57 ± 1.6 for the control ($N=7$) and 9.83 ± 1.1 for β -caryophyllene-treated rats ($N=6$). Number of resorption sites was 0 ± 0 for both groups. In implantation experiment number of implant sites was 7.971 ± 1.4 for the control ($N=7$) and 9.00 ± 1.1 for β -caryophyllene-treated rats ($N=6$). Number of resorption sites was 0 ± 0 for both groups. Results of mid-gestation, late abortion and normal delivery experiments are shown in Table 3. Similarly, no statistically significant difference in all studied parameters was found including number of embryos, resorption sites, number of corpora lutea, number and weight of fetuses, number and weight of newborns. In normal delivery experiment, parturition was at day 22–23 of pregnancy in animals of both control and β -caryophyllene-treated group.

4. Discussion

4.1. Regression of endometrial explants

In this study, β -caryophyllene caused regression of endometrial implants by 52.5% (10 mg/kg dose) and by 41.0% (30 mg/kg dose). Up to our best knowledge, this is the first time the effect of

β -caryophyllene on endometriosis is reported. No statistically significant difference was found between the two used doses of β -caryophyllene. Failure of dose-response relationship could result from the saturation of receptors at low doses so that high doses may not give a higher response. The anti-endometriotic effect of β -caryophyllene may be attributed to the well known anti-inflammatory properties of β -caryophyllene. In rat carrageenan-induced paw edema model, β -caryophyllene diminished the production of prostaglandin E_2 , tumor necrosis factor- α (TNF- α) release and the expression of inducible nitric oxide synthase and cyclooxygenase-2 (COX-2) (Fernandes et al., 2007). More recently, it was demonstrated that β -caryophyllene exerts

anti-inflammatory activity by acting as a potent, selective and non-psychoactive full agonist for CB₂ receptor *in vivo* (Gertsch, 2008).

Many studies have shown that COX-2 inhibition was effective in animal models for the treatment of endometriosis (Dogan et al., 2004; Ozawa et al., 2006). Also, TNF- α is a key factor in inflammatory processes in endometriosis (Braun et al., 2002; D'Antonio et al., 2000; D'Hooghe et al., 2006; Dmowski and Braun, 2004). This may explain, at least in part, the effect of β -Caryophyllene on regression of endometrial explants in our work.

4.2. Interpretation of light and electron microscopic results

Light and electron microscopic studies revealed that mast cells exhibited degranulation in the vehicle-treated control rat cysts (Fig. 4B) as well as in β -caryophyllene-treated rat cysts. Ultrastructural studies also demonstrated that many mast cells are activated in both control and β -caryophyllene-treated groups as

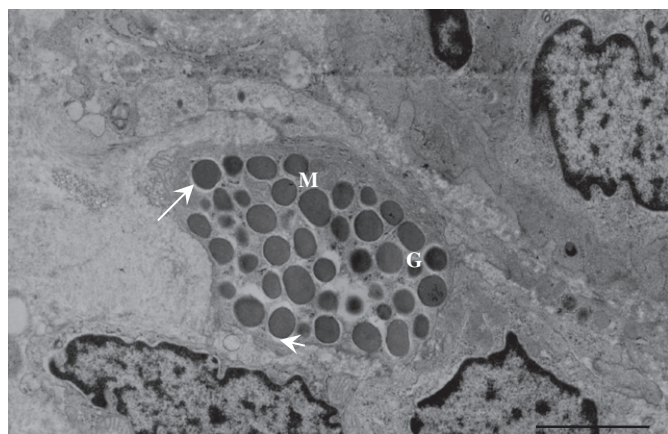


Fig. 5. Electron micrograph of a mast cell of a β -caryophyllene-treated rat. This image shows a mast cell containing granules with variable electron densities. A perigranular space separates the perigranular membrane from the granule matrix (arrow). G, granule; M, mast cells; N, nucleus. Scale bar=2.2 μ m.

Table 2
Distance of blood vessels from aortic ring.

Concentration	Control (DMSO)	1 μ M	10 μ M	100 μ M
Average (mm)	26.7	25.26	31.80	13.08 ^a
Standard deviation	0.47	2.96	3.48	4.48
% Inhibition		5.4	-19.1	51.0

^a Statistically significant difference $p < 0.05$.

Table 3
Effect of β -caryophyllene on mid-gestation, late gestation, normal delivery.

Experiment	Treatment	Number of living fetuses	Number of corpora lutea	Weight of fetus/pups (gm)
Mid-gestation	Control, N=6	9.00 \pm 1.2	10.33 \pm 1.3	0.235 \pm 0.031
	β -Caryophyllene, N=6	9.50 \pm 2.0	11.50 \pm 1.6	0.254 \pm 0.023
Late gestation	Control, N=6	9.16 \pm 1.7	13.67 \pm 3.3	3.30 \pm 0.26
	β -Caryophyllene, N=6	9.50 \pm 1.7	11.33 \pm 1.2	3.29 \pm 0.30
Normal delivery	Control, N=5	8.20 \pm 1.4		4.82 \pm 0.65
	β -Caryophyllene, N=5	7.60 \pm 1.3		4.62 \pm 0.57

Values are mean \pm S.D. No statistically significant difference was found in all studied parameters. N: number of rats.

shown in Figs. 4A and 5 in which granules showed reduced electron density. Singh et al. (1999) suggested that this loss of electron density of granules indicates secretory activity. Furthermore, small vesicles containing electron-dense material were seen in specimens of the control group (Fig. 4A). This may indicate the presence of another form of secretion in endometriotic mast cells known as piecemeal degranulation. This form of secretion operates by emptying individual granules through vesicular transport of "small pieces" of granule contents, finally leaving empty granule containers in place in the cytoplasm (Dvorak, 1991).

Electron microscopic analysis revealed the presence of activated eosinophils in both treated and non-treated groups. Eosinophils in both groups had granules with dark crystals and granules with light crystals (Fig. 4A). According to Miller et al. (1966), specific granules in eosinophils show dense cores that contains a crystal of major basic protein. Secretion of this protein contributes to the immunopathogenesis of varied diseases (Melo et al., 2009). Another way by which eosinophils can release their secretory granule contents is by cytolysis. Eosinophil cytolysis was observed in specimens of β -caryophyllene-treated rat cysts. This form of content secretion is defined by the presence of chromatolysis with loss of plasma membrane integrity (Erjefalt et al., 1998).

4.3. TUNEL assay

The results of the present work demonstrated for the first time that β -caryophyllene induced apoptosis in endometrial luminal epithelium *in vivo*. It was recently shown that CB₂ receptor activation induces apoptosis through *de-novo* ceramide synthesis in colon cancer cells, with tumor necrosis factor (TNF)- α acting as a link between CB receptor activation and ceramide production (Cianchi et al., 2008). Further studies are needed to explore the apoptotic pathway involved.

4.4. Anti-angiogenic effect of β -caryophyllene

Using aortic ring assay, this study demonstrated for the first time that β -caryophyllene exhibits anti-angiogenic activity. However, the anti-angiogenic activity was detectable only at substantially high concentration (100 μ M). The results of TUNEL assay have shown that some endothelial cells exhibited apoptotic cell death *in vivo*. This may contribute to the regression of endometrial implants in the utilized rat surgical model employed. Different studies suggested that angiogenesis plays an essential role in the pathogenesis of endometriosis (Taylor et al., 2002). Also, it has been suggested that COX-2 selective inhibitors could be effective in suppressing the establishment and growth of endometriosis – at least partially – through their anti-angiogenic activity (Machado et al., 2010). Furthermore, different cannabinoid compounds with varying CB₁ and CB₂ receptor

affinities decreased the formation of new blood vessels. Since β -caryophyllene exhibits potent CB₂ receptor agonistic activity (Gertsch, 2008), then it may exert its anti-angiogenic activity CB₂ receptor agonism.

4.5. Effect of β -caryophyllene on fertility

It was clear from the results of fertility experiments that β -caryophyllene (50 mg/kg, i.p) has no statistically significant effect on all studied parameters in ovulation, early, middle and late pregnancy and normal delivery. Similarly, Efstathiou et al. (2005) demonstrated that the selective COX-2 inhibitor celecoxib inhibits the growth of endometriotic lesions but did not have a negative effect on the estrous cycle in mice. On the other hand, Gaytan et al. (2006) reported that non-selective and selective COX-2 inhibitors impaired ovulation. A study conducted by Espey (1983) has demonstrated that ovulation was completely inhibited by diclofenac and indomethacin. However, it was partially inhibited by fenoprofen, and unaffected by aspirin, acetaminophen, or dexamethasone. So, it was suggested that the anti-inflammatory agent must completely abolish the preovulatory elevation in prostaglandins in mature follicles in order to totally inhibit ovulation.

5. Conclusion

β -Caryophyllene caused a significant reduction in cyst size and produced apoptosis in endometrial explants without interfering with pregnancy or ovulation. In fact, β -caryophyllene is an FDA-approved food additive (Gertsch et al., 2008) and it is apparently a non-toxic compound with no genotoxic or cytotoxic effect *in vivo* (Molina-Jasso et al., 2009). Clinical studies may prove its effectiveness in treating endometriosis.

Acknowledgments

Financial support: This project was totally financed by the Deanship of Scientific Research at the University of Jordan, Amman.

Authors contribution: Dr. Manal Abbas performed the surgical work, prepared histological sections and prepared the manuscript. Dr. Mutasem O. Taha suggested the use of β -caryophyllene for the treatment of endometriosis and obtained funding.

Dr. Malek A. Zihlif performed aortic ring assay.

Dr. Ahmad M. Disi designed the work, performed fertility study, histological evaluation, supervised data collection, directed data analyses, interpreted results, revised the article critically and obtained funding.

References

- Agic, A., Djalali, S., Diedrich, K., Hornung, D., 2009. Apoptosis in endometriosis. *Gynecol. Obstet. Invest.* 68, 217–223.
- Al-Dissi, N.M., Salhab, A.S., Al-Hajji, H.A., 2001. Effects of *Inula viscosa* leaf extracts on abortion implantation in rats. *J. Ethnopharmacol.* 77, 117–121.
- Braun, D.P., Ding, J., Dmowski, W.P., 2002. Peritoneal fluid-mediated enhancement of eutopic and ectopic endometrial cell proliferation is dependent on TNF- α in women with endometriosis. *Fertil. Steril.* 78, 727–732.
- Brown, K., Maynes, S., Bezos, A., Maguire, D.J., Ford, M.D., Parish, C.R., 1996. A novel *in vitro* assay for human angiogenesis. *Lab. Invest.* 75, 539–555.
- Cianchi, F., Papucci, L., Schiavone, N., 2008. Cannabinoid receptor activation induces apoptosis through tumor necrosis factor α -mediated ceramide de novo synthesis in colon cancer cells. *Clin. Cancer Res.* 14, 7691–7700.
- Couri, D., Miller, C.H., Bull, R.J., Delphat, J.M., Ammar, E.M., 1982. Assessment of maternal toxicity, embryotoxicity and teratogenic potential of sodium chlorite in Sprague-Dawley rats. *Environ. Health Perspect.* 46, 25–29.
- D'Antonio, M., Martelli, F., Peano, S., Papoian, R., Borrelli, F., 2000. Ability of recombinant human TNF binding protein-1 (r-hTBP-1) to inhibit the development of experimentally-induced endometriosis in rats. *J. Reprod. Immunol.* 48, 81–98.
- D'Hooghe, T.M., Kyama, C.K., Mwenda, J.M., 2009. Baboon model for endometriosis. In: Vande Berg, J.L. (Ed.), *The Baboon in Biomedical Research*. Springer Science & Business Media, LLC, pp. 139–156.
- D'Hooghe, T.M., Nugent, N.P., Cuneo, S., Chai, D.C., Deer, F., Debrock, S., Kyama, C.M., Mihalyi, A., Mwenda, J.M., 2006. Recombinant human TNFRSF1A (r-hTBP1) inhibits the development of endometriosis in baboons: a prospective, randomized, placebo- and drug-controlled study. *Biol. Reprod.* 74, 131–136.
- Dmowski, W.P., Braun, D.P., 2004. Immunology of endometriosis. *Best Pract. Res. Clin. Obstet.* 18, 245–263.
- Dogan, E., Saygili, U., Posaci, C., Tuna, B., Caliskan, S., Altunurt, S., Saatli, B., 2004. Regression of endometrial explants in rats treated with the cyclooxygenase-2 inhibitor rofecoxib. *Fertil. Steril.* 82 (Supplement 3), 1115–1120.
- Dvorak, A.M., 1991. Basophil and mast cell degranulation and recovery. In: Harris, J.R. (Ed.), *Blood Cell Biochemistry*, Vol. 4. Plenum Press, New York, pp. 27–65.
- Efstathiou, J.A., Sampson, D.A., Levine, Z., Rohan, R.M., Zurakowski, D., Folkman, J., D'Amato, R.J., Rupnick, M.A., 2005. Nonsteroidal antiinflammatory drugs differentially suppress endometriosis in a murine model. *Fertil. Steril.* 83, 171–181.
- Eltern, M., 2008. Development and Evaluation of Two Mouse Models for Endometriosis Focused on the Involvement of the Immune System in Endometriosis Establishment. Ph. D. thesis, University of Berlin.
- Erjefalt, J.S., Andersson, M., Greiff, L., Korsgren, M., Gizycki, M., Jeffery, P.K., Persson, G.A., 1998. Cytolysis and piecemeal degranulation as distinct modes of activation of airway mucosal eosinophils. *J. Allergy Clin. Immunol.* 102, 286–294.
- Espey, L.L., 1983. Comparison of the effect of nonsteroidal and steroidal antiinflammatory agents on prostaglandin production during ovulation in the rabbit. *Prostaglandins* 26, 71–78.
- Fernandes, E.S., Passos, G.F., Medeiros, R., da Cunha, F.M., Ferreira, J., Campos, M.M., Pianowski, L.F., Calixto, J.B., 2007. Anti-inflammatory effects of compounds α -humulene and (–)-*trans*-caryophyllene isolated from the essential oil of *Cordia verbenacea*. *Eur. J. Pharmacol.* 569, 228–236.
- Gaytan, M., Bellido, C., Morales, C., Sanchez-Criado, J.E., Gaytan, F., 2006. Effects of selective inhibition of cyclooxygenase and lipooxygenase pathways in follicle rupture and ovulation in the rat. *Reproduction* 132, 571–577.
- Gertsch, J., 2008. Anti-inflammatory cannabinoids in diet towards a better understanding of CB₂ receptor action. *Commun. Integr. Biol.* 26–28.
- Gertsch, J., Leonti, M., Raduner, S., Racz, I., Chen, J.Z., Xie, X.Q., Altmann, K.H., Karsak, M., Zimmer, A., 2008. Beta-caryophyllene is a dietary cannabinoid. *Proc. Natl. Acad. Sci. USA* 105, 9099–9104.
- Hart, E.R., Wong, L.C.K., 1971. Acute Oral Toxicity Studies in Rats, Acute Dermal Toxicity and Primary Skin Irritation Studies in Rabbits of 17 Fragrance Materials. Bionetics Research Laboratories. July 30, Report Submitted by EFAA to SCF.
- Hendriks, H., Malingre, T., Battermann, S., Boss, R., 1975. Mono- and sesquiterpene hydrocarbons of the essential oil of *Cannabis sativa*. *Phytochemistry* 14, 814–815.
- Hijazi, A.M., Salhab, A.S., 2010. Effects of *Artemisia monosperma* ethanolic leaves extract on implantation, mid-term abortion and parturition of pregnant rats. *J. Ethnopharmacol.* 128, 446–451.
- Jayaprakasha, G.K., Rao, J.M., Sakariah, K.K., 2003. Volatile constituents from *Cinnamomum zeylanicum* fruit stalks and their antioxidant activities. *J. Agric. Food Chem.* 51, 4344–4348.
- Karnovsky, M.A., 1965. Formaldehyde-glutaraldehyde fixative of high osmolality for use in electron microscopy. *J. Cell Biol.* 27, 137–138.
- Machado, D.E., Berardo, P.T., Landgraf, R.G., Fernandes, P.D., Palmero, C., Alves, L.M., Abrao, M.S., Nasciutti, L.E., 2010. A selective cyclooxygenase-2 inhibitor suppresses the growth of endometriosis with an antiangiogenic effect in a rat model. *Fertil. Steril.* 93, 2674–2679.
- Marcondes, F.K., Bianchi, F.J., Tanno, A.P., 2002. Determination of the estrous cycle phases of rats: some helpful considerations. *Braz. J. Biol.* 62, 609–614.
- Melo, R.C.N., Spencer, L.A., Perez, S.A.C., Neves, J.S., Bafford, S.P., Morgan, E.S., Dvorak, A.M., Weller, P.F., 2009. Vesicle-mediated secretion of human eosinophil granule-derived major basic protein. *Lab. Invest.* 89, 769–781.
- Miller, F., De Harven, E., Palade, G.E., 1966. The structure of eosinophil leukocyte granules in rodents and in man. *J. Cell Biol.* 31, 349–362.
- Mockute, D., Bernotiene, G., Judzentiene, A., 2001. The essential oil of *Origanum vulgare* L. ssp. *vulgare* growing wild in Vilnius district (Lithuania). *Phytochemistry* 57, 65–69.
- Molina-Jasso, D., Ivarez-Gonzalez, I., Madrigal-Bujaidar, E., 2009. Clastogenicity of beta-caryophyllene in mouse. *Biol. Pharm. Bull.* 32, 520–522.
- Nicosia, R.F., Lin, Y.J., Hazelton, D., Qian, X.H., 1997. Endogenous regulation of angiogenesis in the rat aorta model: role of vascular endothelial growth factor. *Am. J. Pathol.* 151, 1379–1386.
- Nothnick, W.B., Zhang, X., 2009. Future targets in endometriosis treatment, targeting the endometriotic implant. *Mini. Rev. Med. Chem.* 9, 324–328.
- Orav, A., Stulova, I., Kailas, T., Muurisepp, M., 2004. Effect of storage on the essential oil composition of piper nigrum I. Fruits of different ripening states. *J. Agric. Food Chem.* 52, 2582–2586.
- Ozawa, Y., Murakami, T., Tamura, M., Terada, Y., Yaegashi, N., Okamura, K., 2006. A selective cyclooxygenase-2 inhibitor suppresses the growth of endometriosis xenografts via antiangiogenic activity in severe combined immunodeficiency mice. *Fertil. Steril.* 86 (Supplement 1), 1146–1151.

- Panay, N., 2008. Advances in the medical management of endometriosis. *Brit. J. Obstet. Gynaecol.* 115, 814–817.
- Rice, V.M., 2002. Conventional medical therapies for endometriosis. *Ann. NY Acad. Sci.* 955, 343–352.
- Sabulal, B., Dan, M., John, A.J., Kurup, R., Pradeep, N.S., Valsamma, R.K., George, V., 2006. Caryophyllene-Rich Rhizome Oil of *Zingiber nimmonii* from South India, chemical characterization and antimicrobial activity. *Phytochemistry* 67, 2469–2473.
- Singh, L.K., Boucher, W., Pang, X., Letourneau, R., Seretakis, D., Green, M., Theoharides, T.C., 1999. Potent mast cell degranulation and vascular permeability triggered by urocortin through activation of corticotropin-releasing hormone receptors. *J. Pharmacol. Exp. Ther.* 288, 1349–1356.
- Sookvanichsilp, N., Pulbutr, P., 2002. Anti-implantation effects of indomethacin and celecoxib in rats. *Contraception* 65, 373–378.
- Story, L., Kennedy, S., 2004. Animal studies in endometriosis, a review. *Institute of Laboratory. Anim. Res.J.* 45, 132–138.
- Taylor, R.N., Lebovic, D.I., Mueller, M.D., 2002. Angiogenic factors in endometriosis. *Ann. NY Acad. Sci.* 955, 89–100 (discussion, vol. 118, pp. 396–406).
- Vernon, M.W., Wilson, E.A., 1985. Studies on the surgical induction of endometriosis in the rat. *Fertil. Steril.* 44, 684–694.
- Zheng, G.Q., Kenney, P.M., Lam, L.K.T., 1992. Sesquiterpenes from clove (*Eugenia caryophyllata*) as potential anticarcinogenic agents. *J. Nat. Prod.* 55, 999–1003.